Place du DTC en neuro réanimation

Transcranial Doppler ultrasound goal-directed therapy for the early management of severe traumatic brain injury.

24 TC graves : GCS 3 – 8 aux urgences

IP > 1.4

Vd < 20 cm/s

Vm < 30 cm/s

OUI → Groupe 1 N = 11

NON → Groupe 2 N = 13

Ract et al Intensive Care Medicine 2007

Transcranial Doppler ultrasound goal-directed therapy for the early management of severe traumatic brain injury.

	Doppler altéré	Doppler Nal
PIC	32±13	22±10**
PPC	73±15	71±14
SvjO2	67±2	72±9

Ract et al Intensive Care Medicine 2007

Intensive Care Med (2007) 33:645–651
DOI 10.1007/s00134-007-0558-6

ORIGINAL

Catherine Ract
Sophie Le Moigno
Nicolas Bruder
Bernard Vigué

Transcranial Doppler ultrasound goal-directed therapy for the early management of severe traumatic brain injury

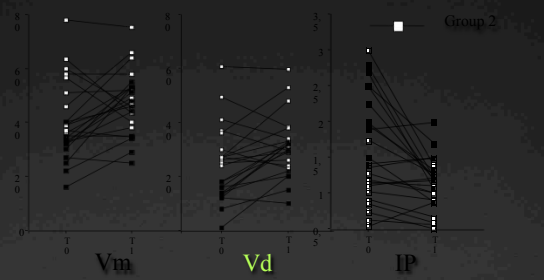

Le Doppler permet de guider le traitement initial

Doppler transcrânien et détection des ACSOS : niveau de PA

110/60 mm Hg

Vmca = 61 cm/s

68/35 mm Hg

Vmca = 34 cm/s

85/37 mm Hg

Vmca = 46 cm/s

115/58 mm Hg

Vmca = 60 cm/s

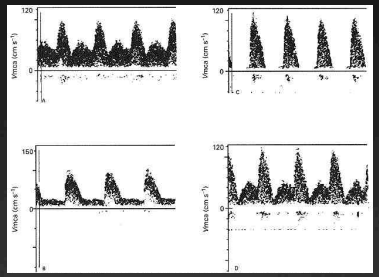

A Lam. *Br J Anaesth*; 1992, 68:424-428

Circulation cérébrale et HIC

PA = 200/90 mm Hg

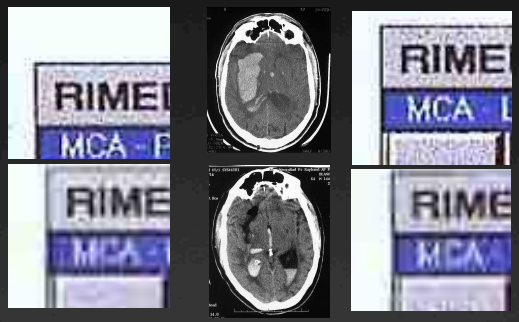

PA = 160/80 mm Hg

Diapo personnelle N Bruder CHU Marseille

Doppler trancrânien :

…monitorage des traitements

Diapo personnelle N Bruder CHU Marseille

Traitement de l'HIC : Mannitol

71	46	51
~~22~~	~~96~~	~~61~~
PIC	PPC	SjO2
mm Hg	mm Hg	%

Avant Mannitol

Après Mannitol

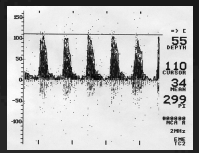

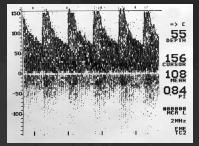

Evolution schématique du DTC lors de l'HTIC

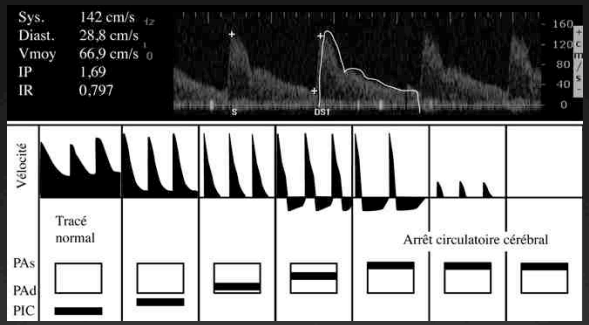

P Zetlaoui SFAR 2009

Doppler trans crânien : choisir le bon moment pour l'angiographie ou l'EEG

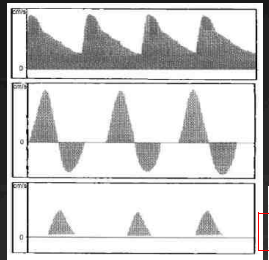

Fig. 1 Transcranial Doppler flow patterns. Transcranial Doppler flow patterns demonstrate normal flow with systolic and diastolic forward flow (*top*), oscillating flow with systolic forward flow and reversed diastolic flow (*middle*), and brief systolic forward flow (*bottom*)

Table 2 Meta-analysis of high quality studies and sensitivity analysis of all included studies. *CI* confidence interval

Primary analysis: only high-quality studies			
		95% CI	
Sensitivity (%)	95	92	97
Specificity (%)	99	97	100
Sensitivity analysis: all studies, Velthoven et al. [24]: cerebral angiography and clinical criteria as reference test			
		95% CI	
Sensitivity (%)	89	86	91
Specificity (%)	99	99	100
Sensitivity analysis: all studies, Velthoven et al. [24]: EEG and clinical criteria as reference test			
		95% CI	
Sensitivity (%)	89	86	91
Specificity (%)	99	98	100

In conclusion, CCA by TCD in the basilar and both middle cerebral arteries correctly predicted fatal brain damage in all patients; therefore, TCD could be used to determine the appropriate moment for angiography. To accept a test for defining brain death, specificity should be 100%. We do believe that further research is needed to demonstrate that repeated TCD examination is able to produce this level of specificity.

Monteiro et al Intensive Care Med 2006

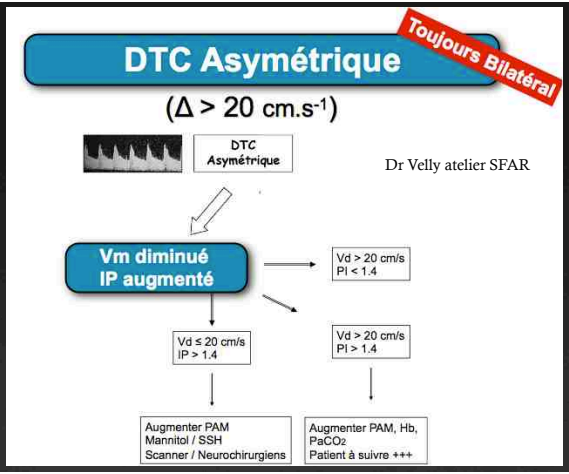

Doppler transcrânien : *valable y compris en cas de gravité moyenne*

Transcranial Doppler to Screen on Admission Patients With Mild to Moderate Traumatic Brain Injury

TABLE 1. Univariate Analysis of Demographic and Biochemical Data Collected on Admission in 98 Patients With Mild to Moderate Traumatic Brain Injury According to Their Neurological Status on Posttrauma Day 7: Patients With and Without Secondary Neurological Deterioration[a]

	No SND (n = 77)	SND (n = 21)	*P*
Age, y	34 (15-84)	46 (20-80)	.04
Sex, M/F	64/13	20/1	.16
Injury type, n			.20
Motor vehicle accident	32	8	
Sports	24	3	
Others	21	10	
Initial GSC score	14 (9-15)	13 (10-15)	<.01
ISS	9 (2-43)	13 (5-41)	<.01
H-AIS	1 (1-4)	3 (3-4)	<.01
Extracranial injuries (yes/no), n	40/37	13/8	.57
Heart rate, bpm	78 (49-119)	75 (44-120)	.46
MAP, mm Hg	90 (60-114)	93 (64-158)	.69
Hemoglobin, g/dL	14.0 (8.0-18.6)	13.5 (7.0-16.8)	.03
Serum sodium, mmol/L	141 (133-149)	140 (135-146)	.33
Mechanical ventilation (yes/no), n	10/67	11/10	<.01
Vasoactive agents (yes/no), n	3/74	8/13	<.01
TCDB I/II	53/24	0/21	<.01
Injury-to-CT time, min	180 (65-540)	120 (15-210)	<.01

- SND = secondary neurological deterioration
- = perte de 2 points de Glasgow

TABLE 2. Univariate Analysis of Transcranial Doppler Measurements Collected on Admission in 98 Patients With Mild to Moderate Traumatic Brain Injury According to Their Neurological Status on Posttrauma Day 7: Patients With and Without Secondary Neurological Deterioration[a]

	No SND (n = 77)	SND (n = 21)	*P*
FVm, cm/s	49 (31-80)	31 (18-60)	<.01
FVs, cm/s	84 (47-128)	69 (38-119)	<.01
FVd, cm/s	34 (18-64)	18 (11-36)	<.01
Pulsatility index	1.02 (0.66-1.83)	1.47 (1.07-2.33)	<.01
Injury-to-TCD time, min	215 (42-700)	300 (90-690)	.03

Bouzat et al Neurosurgery 2011

Doppler transcrânien : *valable y compris en cas de gravité moyenne*

TABLE 3. Threshold Values and the Corresponding Sensitivity, Specificity, and Positive and Negative Likelihood Ratios of Each Transcranial Doppler Parameter[a]

TCD Parameter	Cutoff	Sensitivity, %	Specificity, %	Correctly Classified, %	PLR	NLR
FVm	33 cm/s	99	52	89	2.1	0.02
FVs	58 cm/s	95	33	82	1.4	0.16
FVd	25 cm/s	92	76	89	3.9	0.10
PI	1.25	90	91	91	9.9	0.10

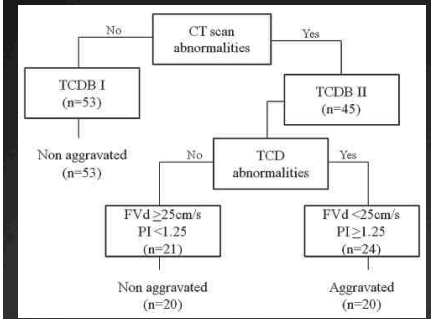

Bouzat et al Neurosurgery 2011

Doppler transcrânien : *test d'autorégulation cérébrale*

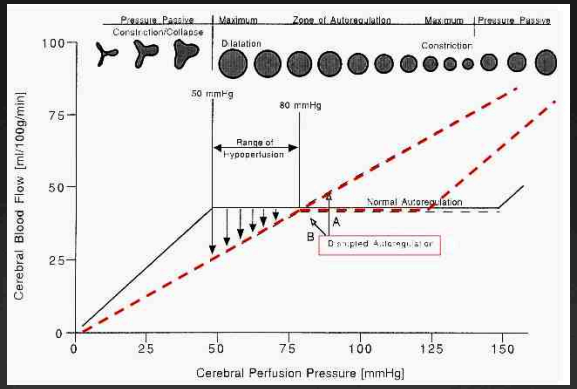

Doppler transcrânien : *test d'autorégulation cérébrale*

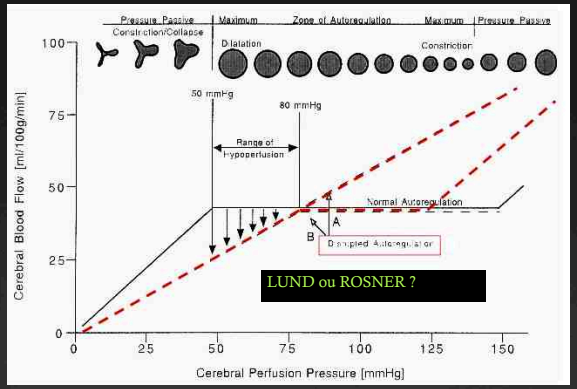

Doppler transcrânien : *test d'autorégulation cérébrale*

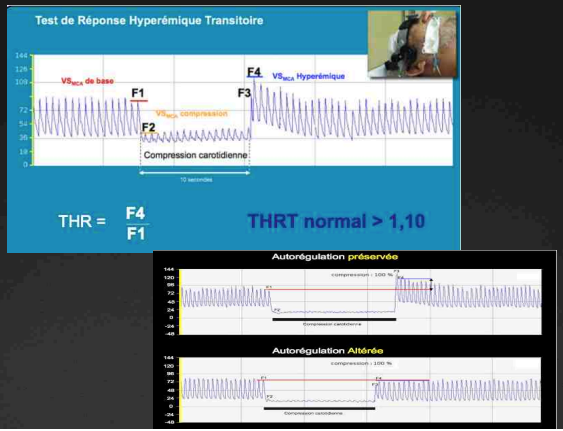

Doppler transcrânien : monitorage continu

Reactivité CO2 : attention !!

PCO2=45mmHg
PIC=44mmHg
PPC=54mmHg
DSC global=59ml/min/100g

PCO2=30mmHg
PIC=15mmHg
PPC=82mmHg
DSC global=14ml/min/100g
avec des débits régionaux <10ml/min/100g = seuil d'ischémie irréversible

Ne pas se focaliser que sur la PIC pour ne pas manquer sa cible = le DSC

Doppler transcrânien : ***HSA et vasospasme***

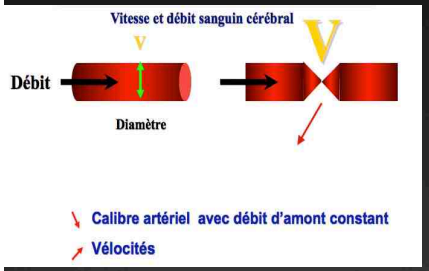

ACM +++
TB +
> 85 cm/s
ACA +
> 100 cm/s

50cm/s des vitesses en *24h* ou /côté *controlatéral*

Doppler transcrânien : ***HSA et vasospasme***

AC
M

V moy < 120 cm/s:	normalité
V moy > 200 cm/s:	vasospasme sévère
120 < V moy < 200:	vasospasme modéré

Index de Lindergaard

Vm MCA / Vm ICA	<3 Hyperhémie
	> 3 Vasospame modéré
	> 6 Vasospame sévère

Echo Doppler transcrânien : ***mais aussi ….***

. Visualisation anevrysme, MAV, hydrocéphalie

. mesure de la DLM

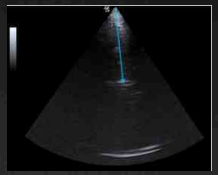

. Quantification volume hématome

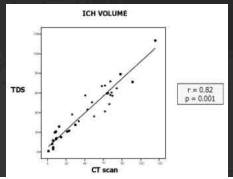

Echo Doppler transcrânien : *mais aussi ….*

- Encéphalopathie hépatique
- Méningo-encéphalite infectieuse

Aide au monitoring
Evaluation non invasive de la PIC

- Sonothrombolyse dans l'AVC ischémique

Alexandrov et al, *Stroke*, 2004

Echo Doppler transcrânien : *mais aussi ….*



Echo Doppler transcrânien : *mais aussi ….*

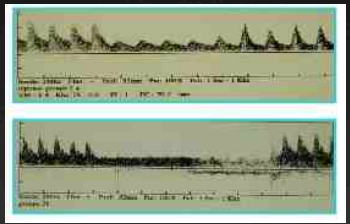

Dissection carotidienne

Echo Doppler transcrânien : *limites*

Transcranial Doppler Pulsatility Index: Not an Accurate Method to Assess Intracranial Pressure

Neurosurgery 66:1050-1057, 2010

Reliability of the Blood Flow Velocity Pulsatility Index for Assessment of Intracranial and Cerebral Perfusion Pressures in Head-Injured Patients

CONCLUSION: Overall, the value of TCD-PI to assess ICP and CPP noninvasively is very limited. However, extreme values of PI can still potentially be used in support of a decision for invasive ICP monitoring.

KEY WORDS: Cerebral perfusion pressure, Critical care, Diagnostic value, Head injury, Intracranial pressure, Pulsatility index

Neurosurgery 71:853–861, 2012 DOI: 10.1227/NEU.0b013e318265d3e3 www.neurosurgery-online.com

Faux positif …

Maria Ahmad
Matthieu Legrand
Anne-Claire Lukaszewicz
Philippe Charlier
Joaquim Mateo
Didier Payen

Transcranial Doppler monitoring may be misleading in prediction of elevated ICP in brain-injured patients

Intensive Care Med
DOI 10.1007/s00134-013-2885-0

CORRESPONDENCE

Echo Doppler transcrânien : *limites, fenêtre temporale*

réduite avec age (notamment si sexe féminin :Pb de l'os ostéoporotique)

Absente dans 10 à 15 % des cas

Utilisation de produits de contraste pour ultra sons : SONOVUE

Fenetre alternative : trans orbitaire (siphon carotidien)

Technique alternatives : épaisseur de l'enveloppe du nerf optique

Doppler intra crânien : approche trans orbitaire

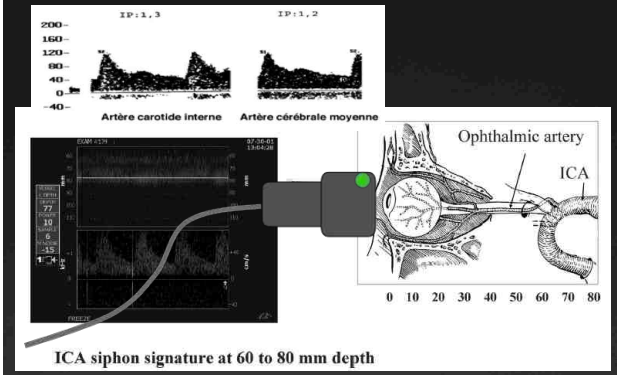

Saqqur et al Crit Care Med 2007

Echographie de l'enveloppe du nerf optique

Neurochirurgie 58 (2013) 55–59

Disponible en ligne sur SciVerse ScienceDirect www.sciencedirect.com

Elsevier Masson France EM|consulte www.em-consulte.com

Revue générale

Intérêt de l'échographie du diamètre de l'enveloppe du nerf optique pour la détection non invasive de l'hypertension intracrânienne

Interest of optic nerve sheath diameter ultrasonography in dectecting non-invasively raised intracranial pressure

M. Messerer[a], M. Berhouma[b,c], R. Messerer[c], J. Dubourg[b,d,*]

Echographie de l'enveloppe du nerf optique

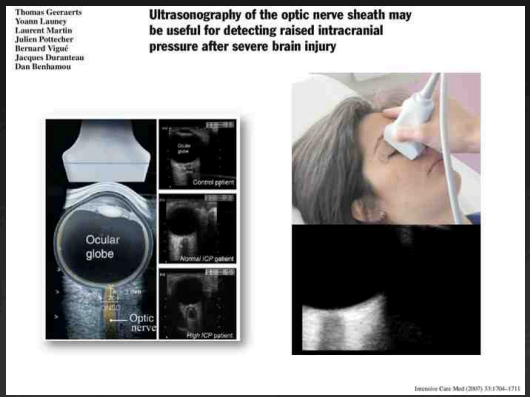

Thomas Geeraerts
Yoann Launey
Laurent Martin
Julien Pottecher
Bernard Vigué
Jacques Duranteau
Dan Benhamou

Ultrasonography of the optic nerve sheath may be useful for detecting raised intracranial pressure after severe brain injury

Intensive Care Med (2007) 33:1704–1711

Echographie de l'enveloppe du nerf optique

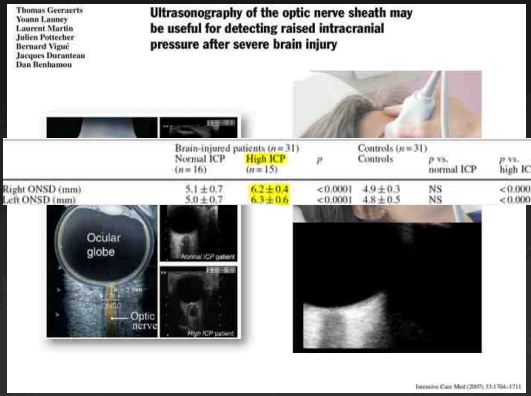

Thomas Geeraerts
Youm Launey
Laurent Martin
Julien Pottecher
Bernard Vigué
Jacques Duranteau
Dan Benhamou

Ultrasonography of the optic nerve sheath may be useful for detecting raised intracranial pressure after severe brain injury

	Brain-injured patients ($n=31$) Normal ICP ($n=16$)	High ICP ($n=15$)	p	Controls ($n=31$) Controls	p vs. normal ICP	p vs. high ICP
Right ONSD (mm)	5.1 ± 0.7	6.2 ± 0.4	<0.0001	4.9 ± 0.3	NS	<0.0001
Left ONSD (mm)	5.0 ± 0.7	6.3 ± 0.6	<0.0001	4.8 ± 0.5	NS	<0.0001

Intensive Care Med (2007) 33:1704–1711

Optic nerve sonography in the diagnostic evaluation of adult brain injury

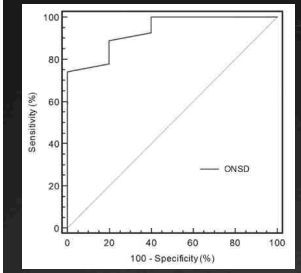

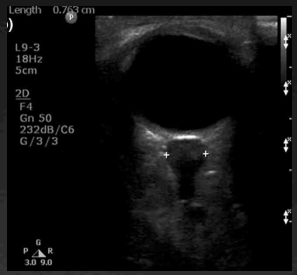

The best cut-off value of ONSD for predicting elevated ICP was 5.7 mm (sensitivity = 74.1% and specificity = 100%).

Soldatos et al Critical Care 2008

DTC : conclusion

Detection

Adaptation therapeutique — lutter contre ischémie cérébrale

Suivi

En tenant compte des limites

Quelques exemples…

- Vd Vm basses
- Bas débit sanguin cérébral (DSC) : olighémie
- IP normal : résistances vasculaires cérébrales (RVC) normales
- OLIGHEMIE SYSTEMIQUE

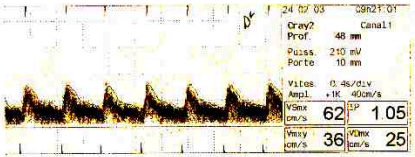

Quelques exemples…

- Vd Vm basse : bas DSC : olighémie
- Vs normale, IP élevé (1,44)

- <u>OLIGHEMIE CEREBRALE</u> (capnie normale?)

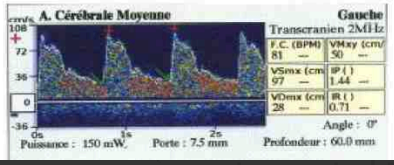

Quelques exemples…

- Élévation Vd Vm : DSC élevé
- Si absence de vasospasme
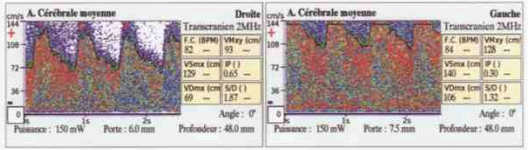
- <u>HYPERHEMIE</u>