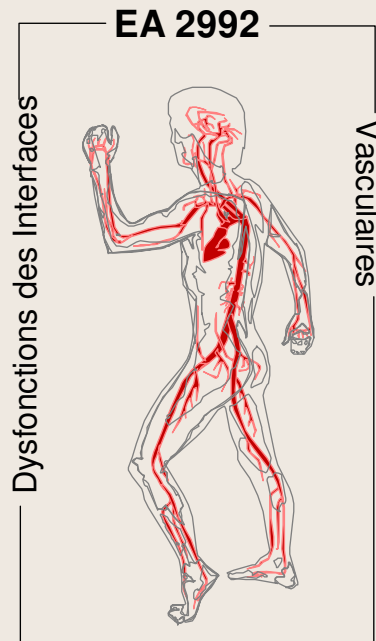
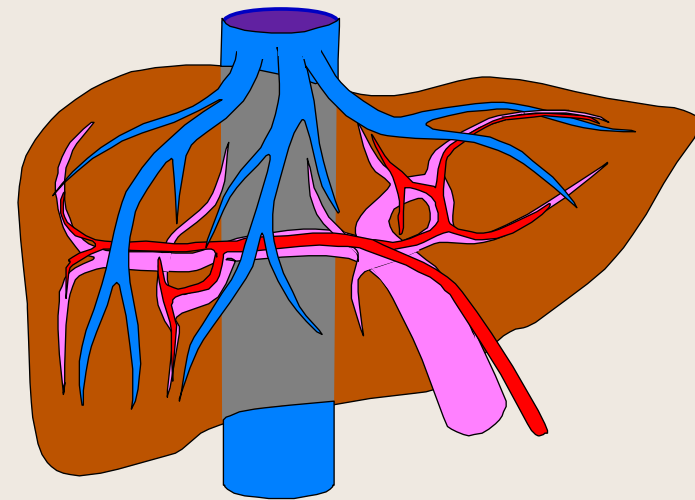


La Circulation Hépatique

- B -

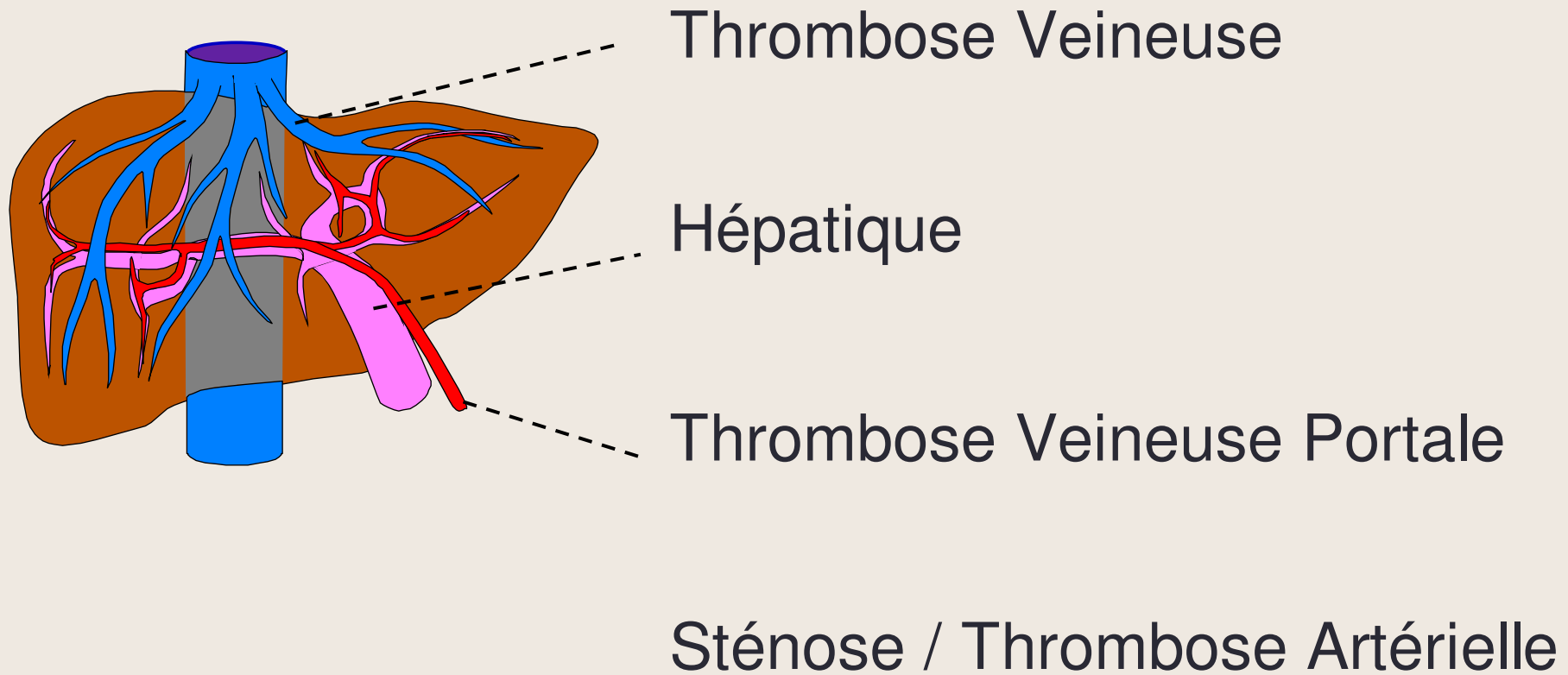


- Michel Dauzat
- Benoît Gallix
- Patrice Taourel
- Michel Lafortune



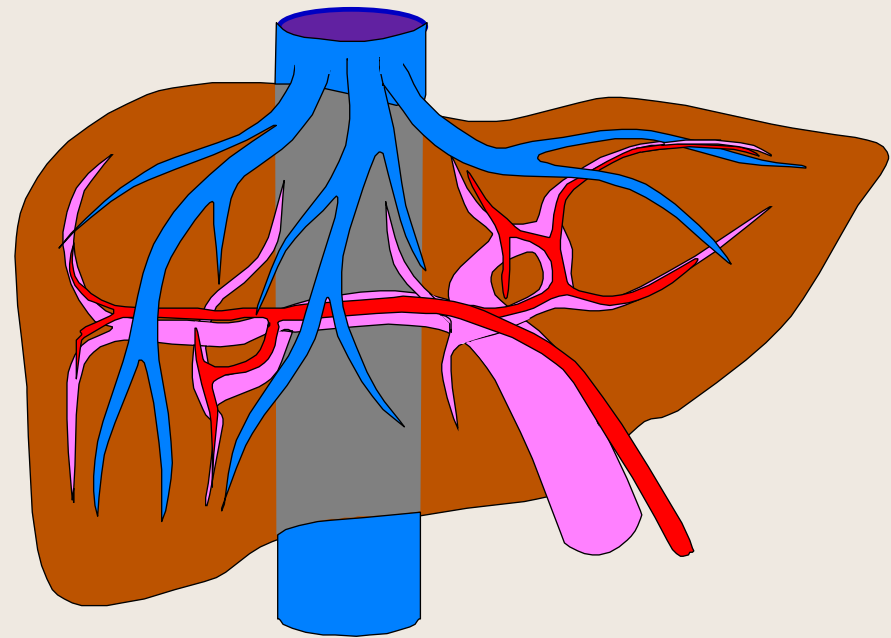
Beaune – Samedi 16 Juin 2012

Pathologie de la Circulation Hépatique

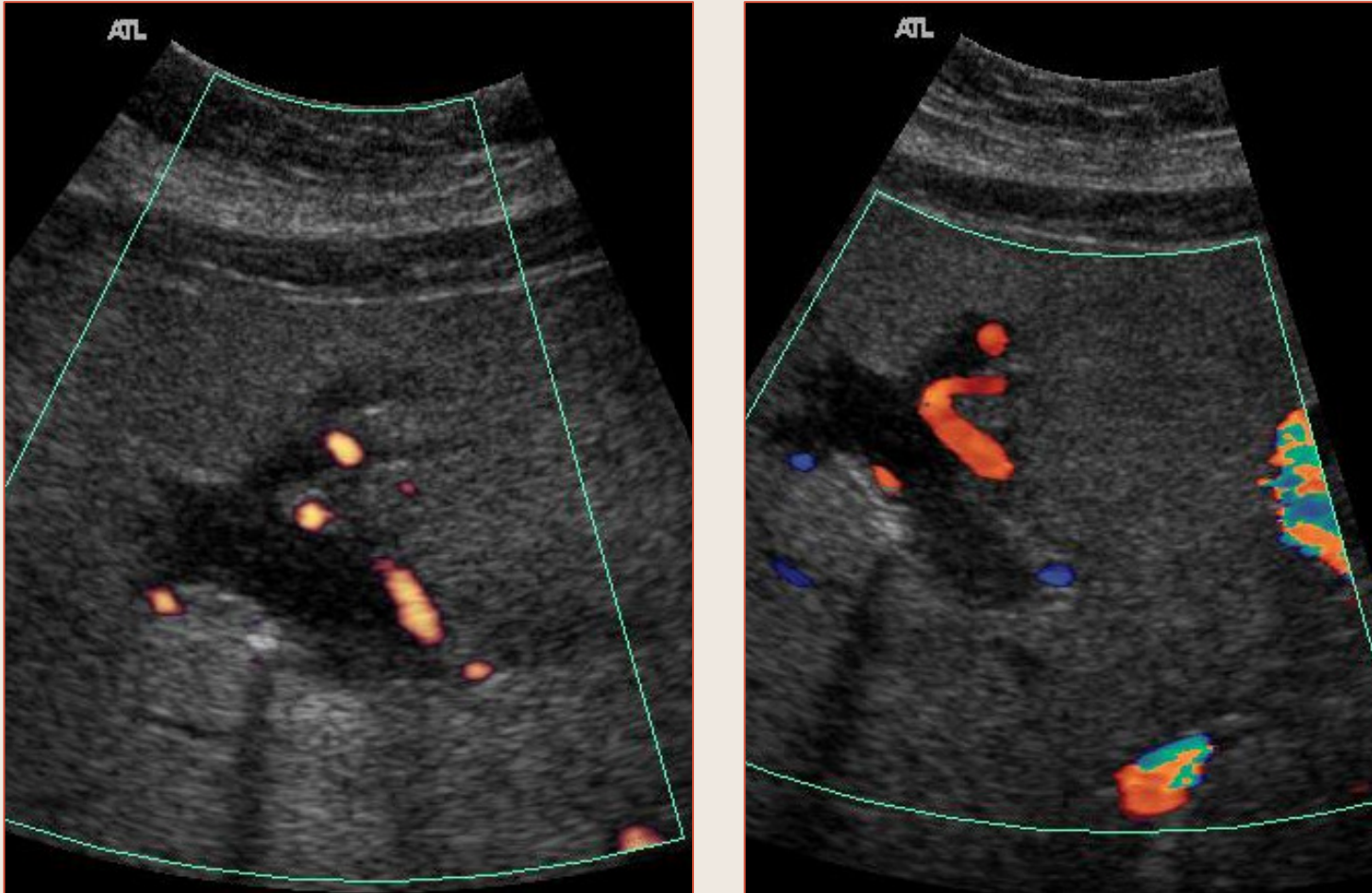


Thrombose de la Veine Porte

- **Aiguë**
 - Signes directs
 - Signes indirects
- **Chronique**
- **Partielle**
- **Totale**

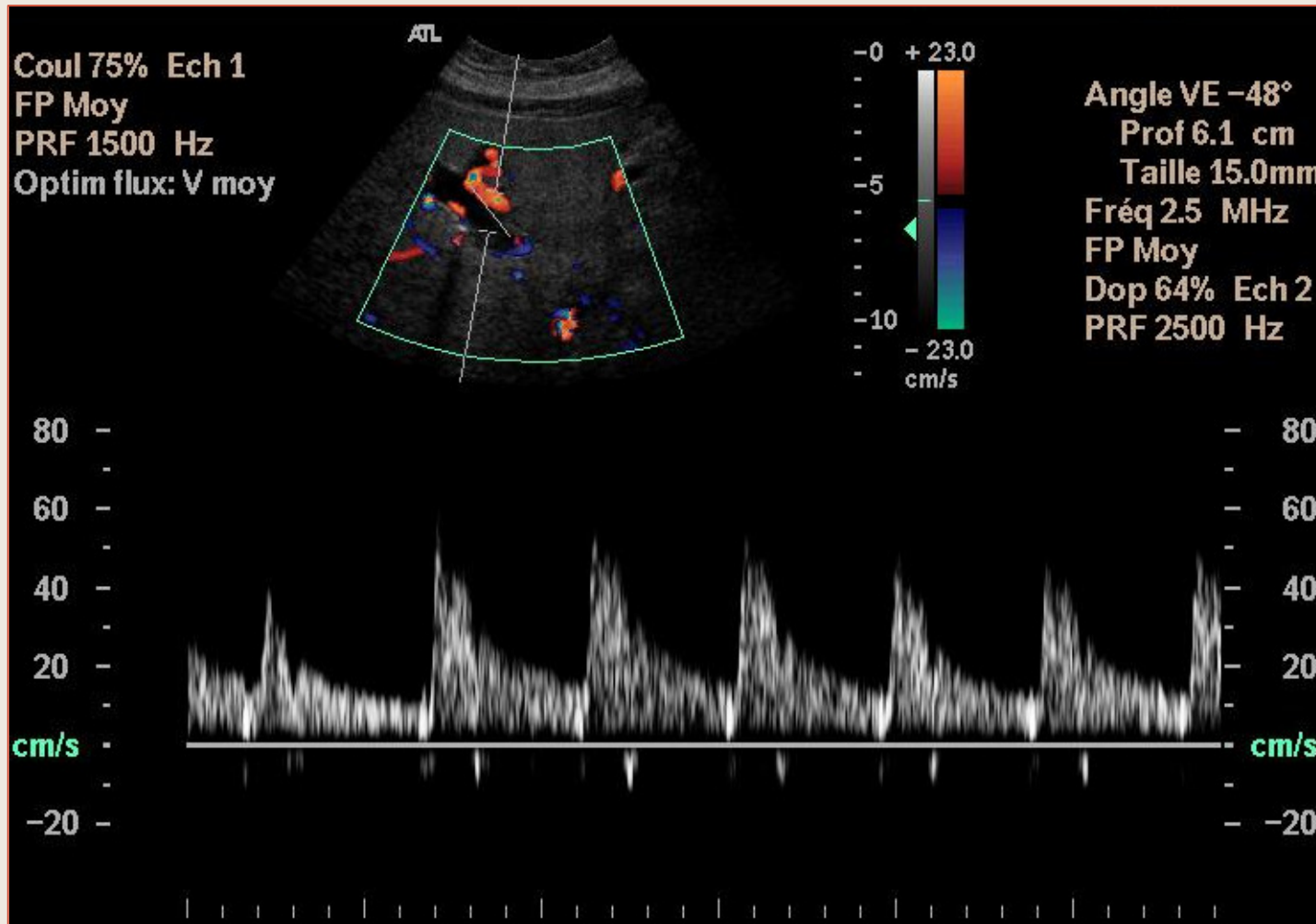


Thrombose Veineuse Portale



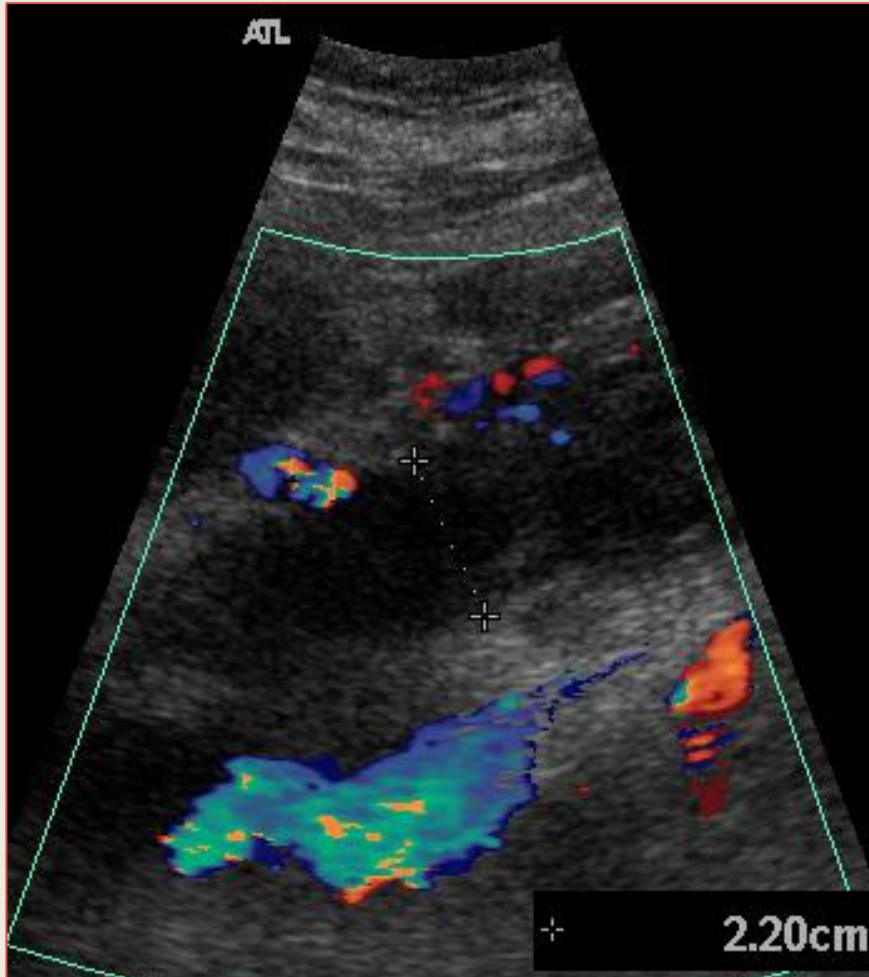
Thrombose de la branche porte gauche

Thrombose Veineuse Portale



Thrombose de la branche porte gauche

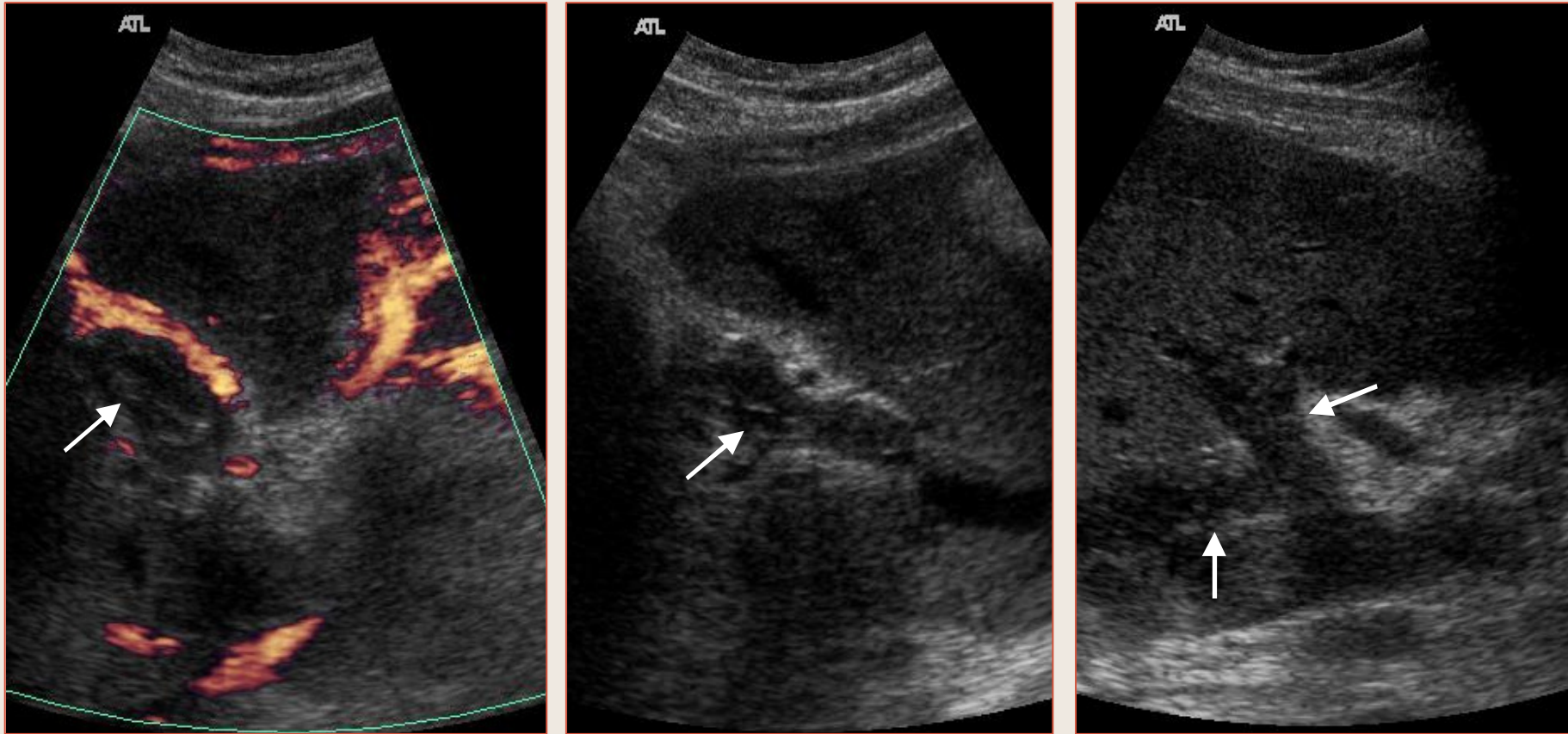
Thrombose Veineuse Portale



*Complication d'une
pancréatite*

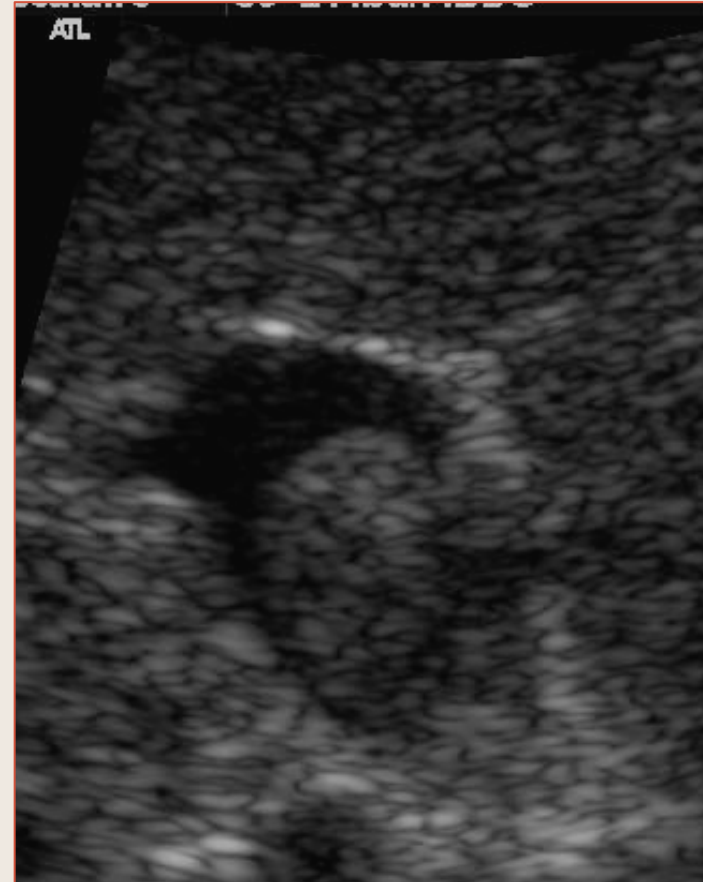
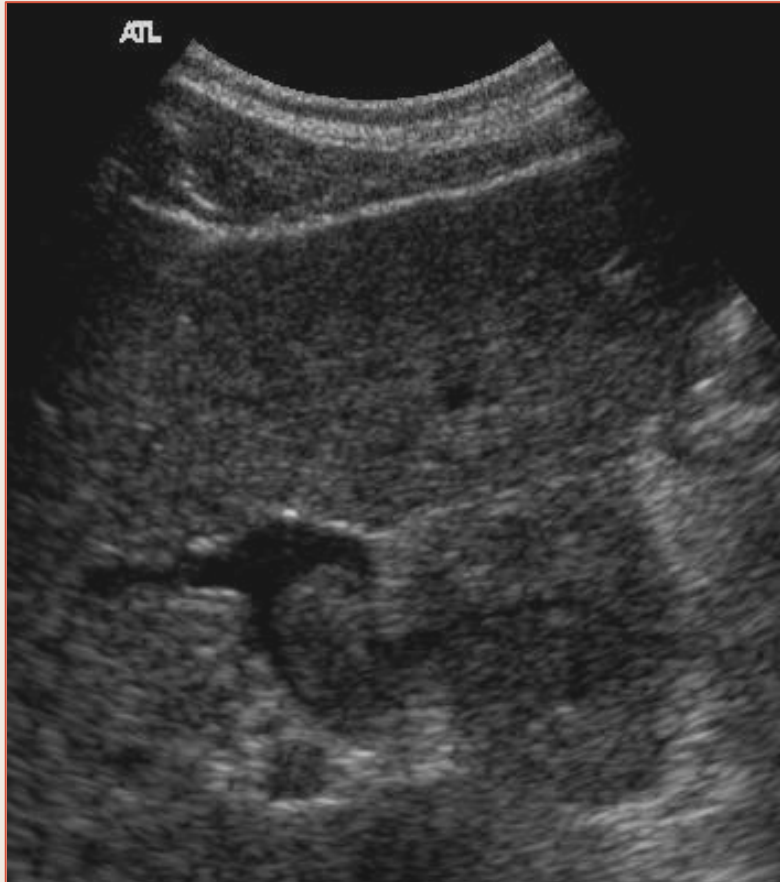Thrombose totale porte et mésentérique

Thrombose Veineuse Portale



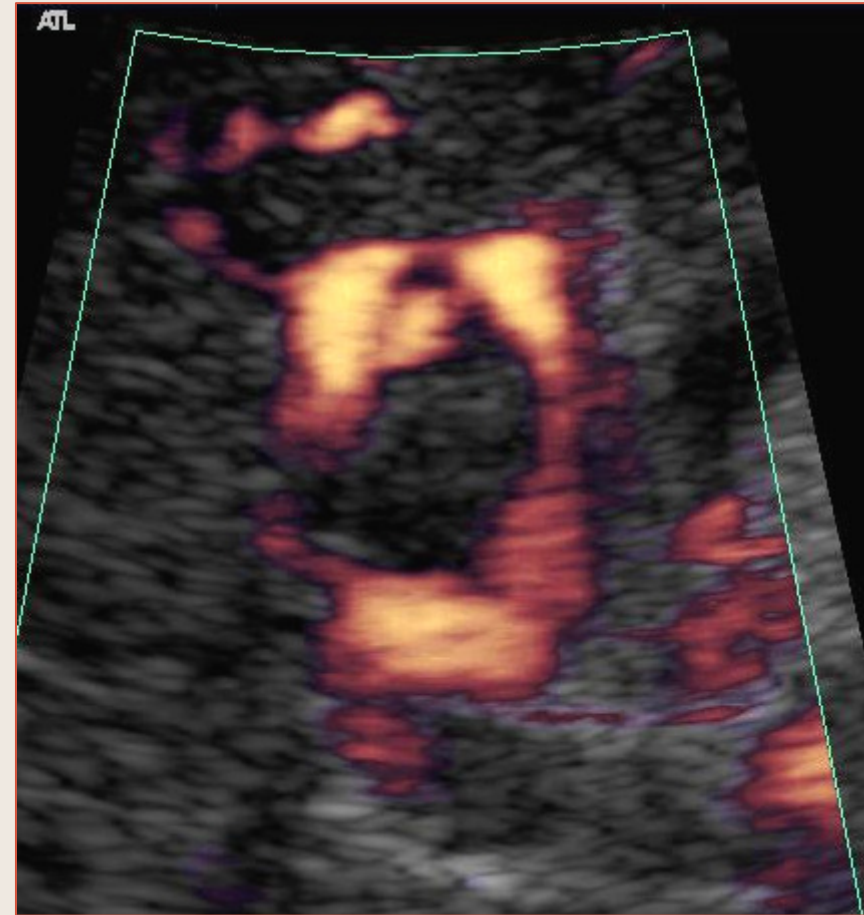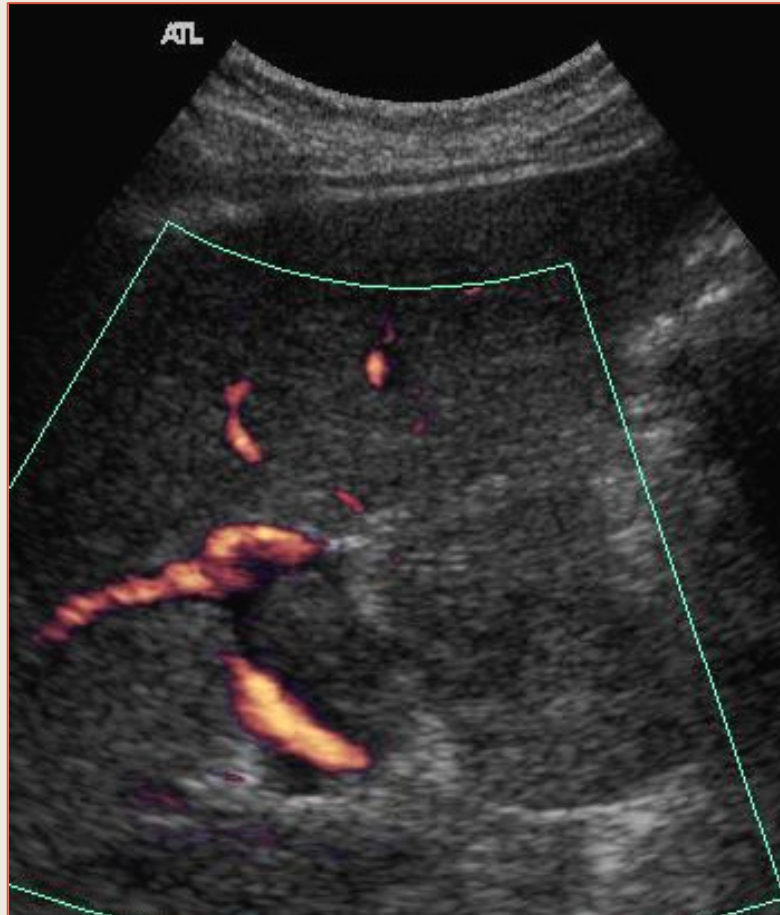
Thrombose totale porte et mésentérique

Thrombose Veineuse Portale



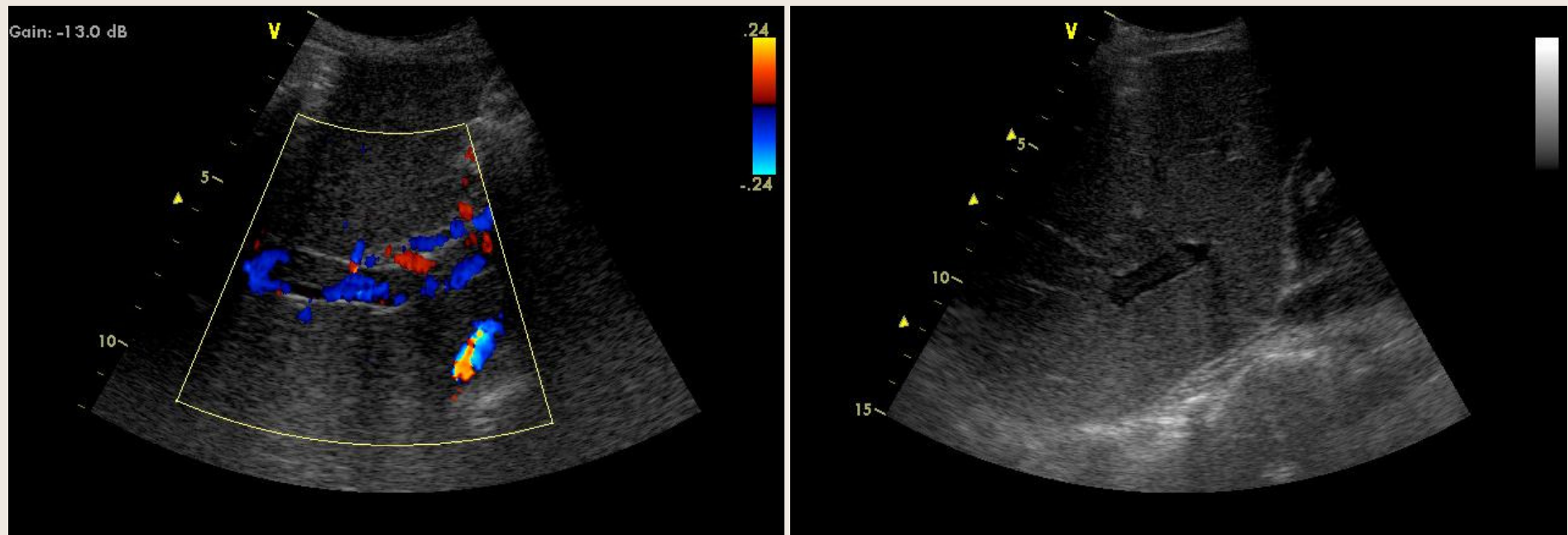
Thrombose partielle de la veine porte gauche
sur cirrhose OH + B + C

Thrombose Veineuse Portale



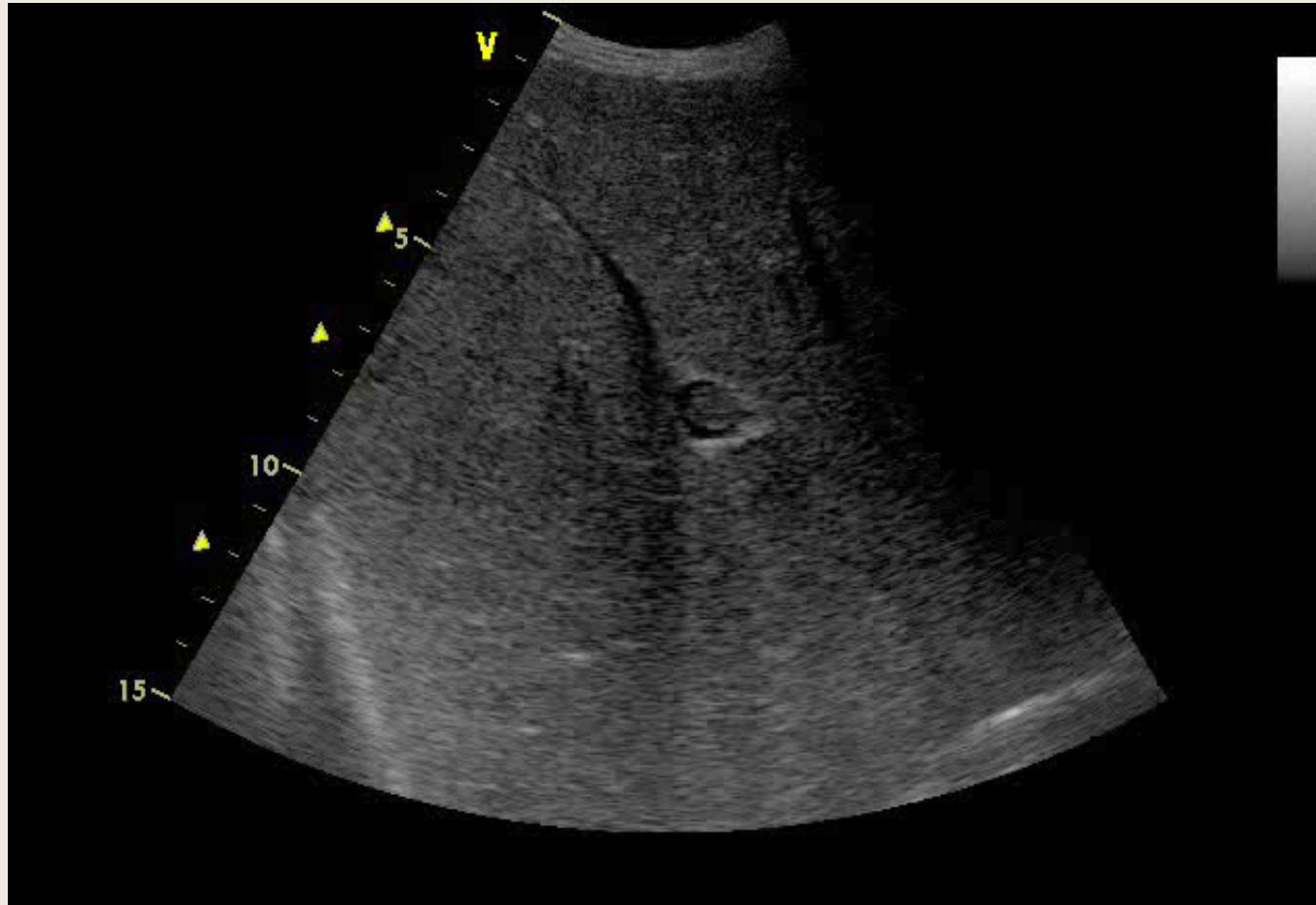
Thrombose partielle de la veine porte gauche
sur cirrhose OH + B + C

Thrombose Veineuse Portale



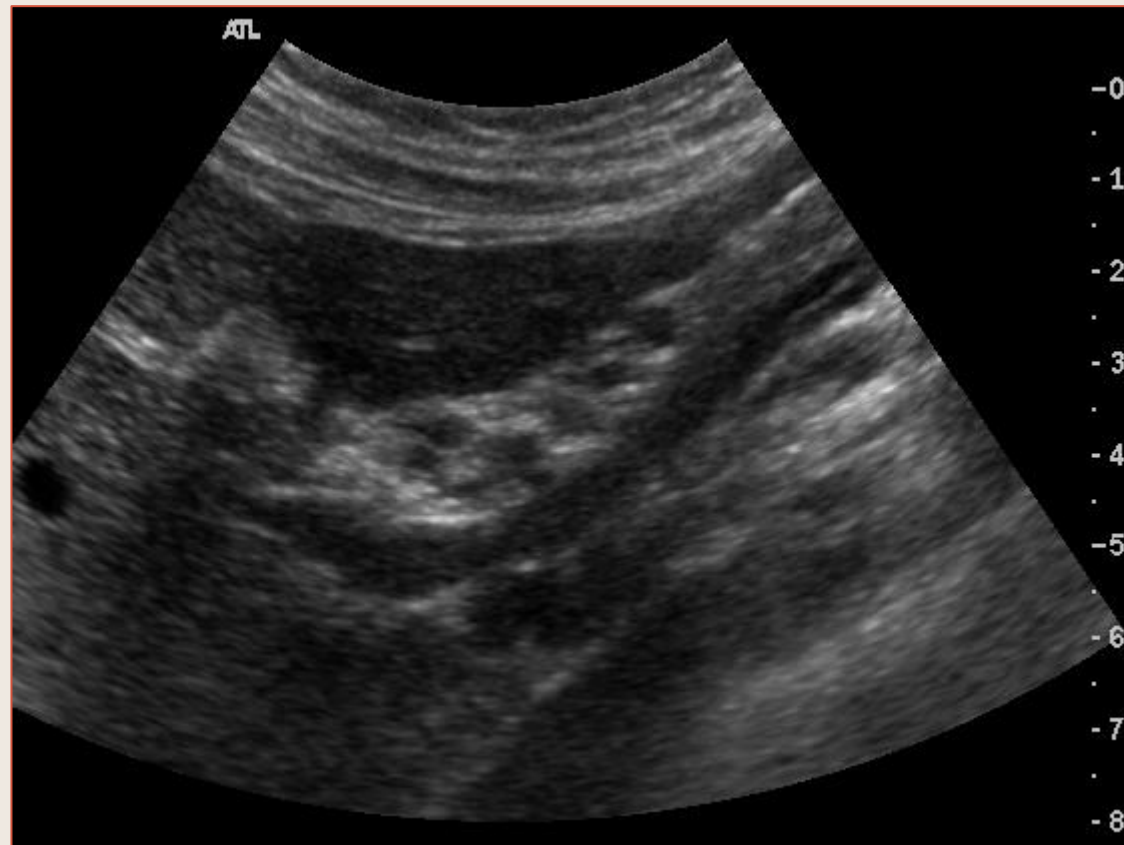
Thrombose partielle de la veine porte droite

Thrombose Veineuse Portale



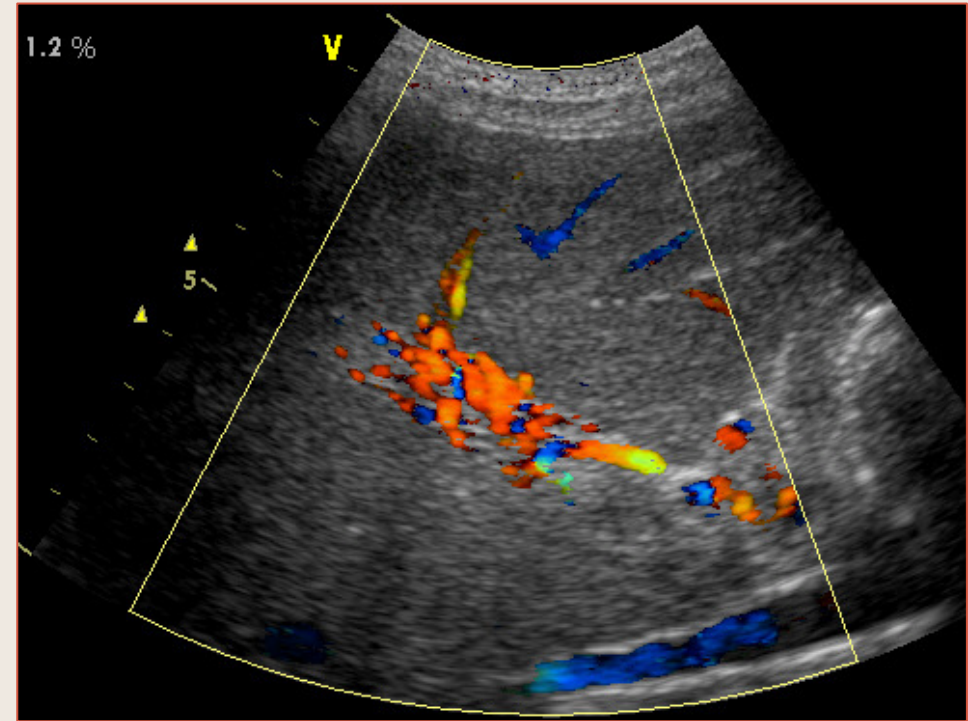
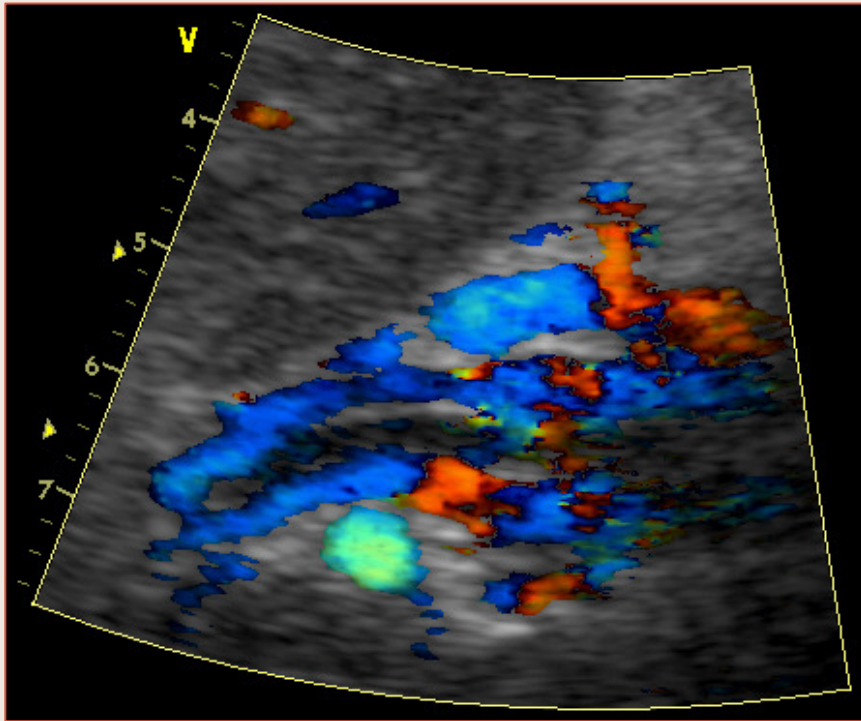
Cavernome portal

Thrombose Veineuse Portale



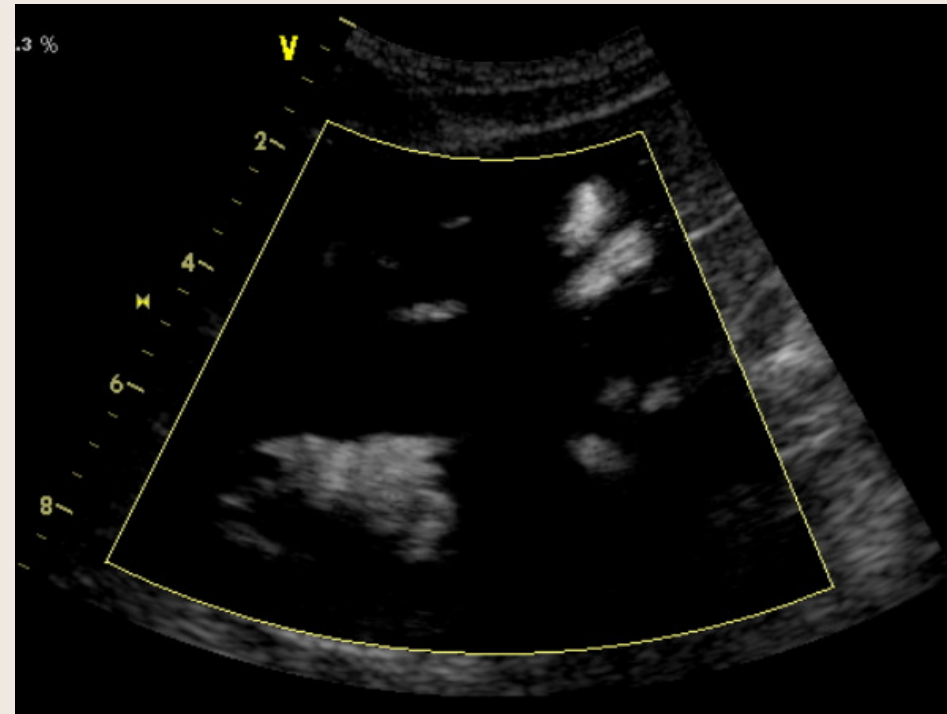
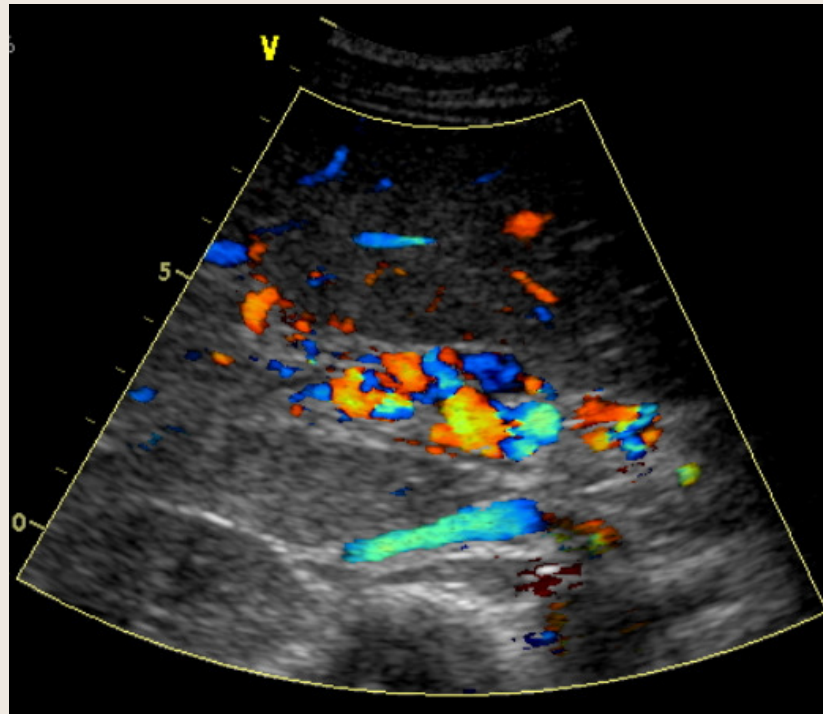
Cavernome portal

Thrombose Veineuse Portale



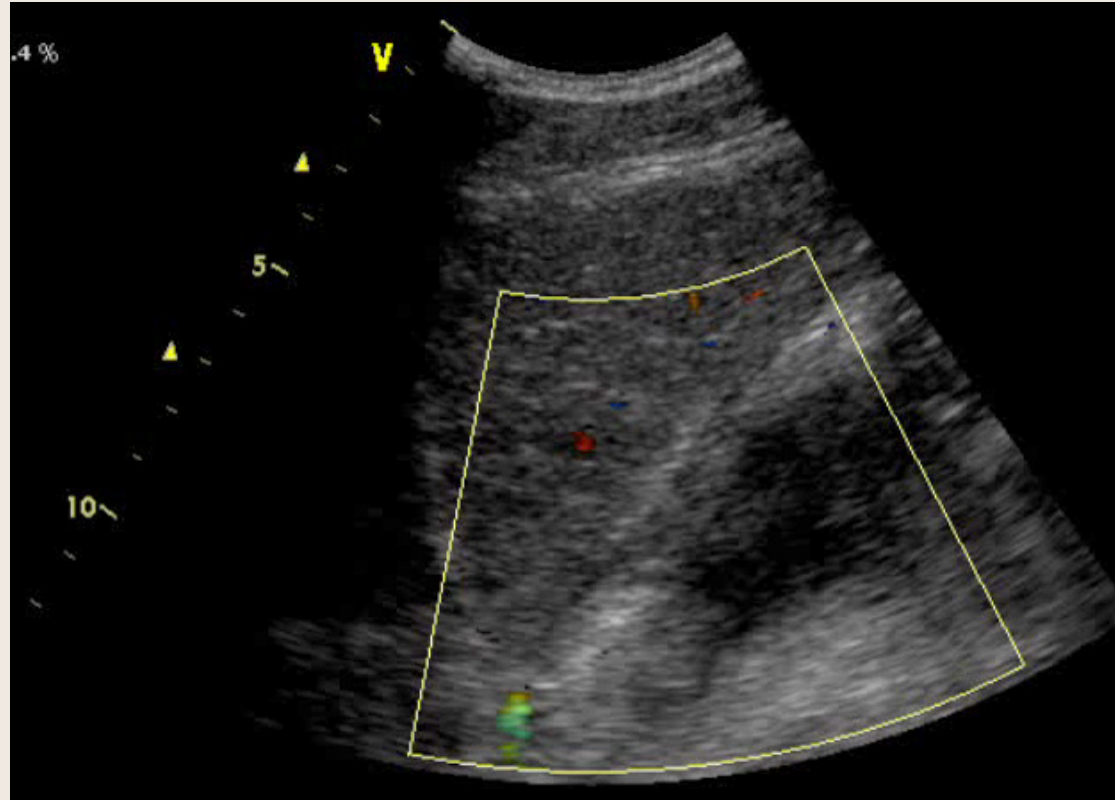
Réinjection portale intra-hépatique après thrombose

Thrombose Veineuse Portale



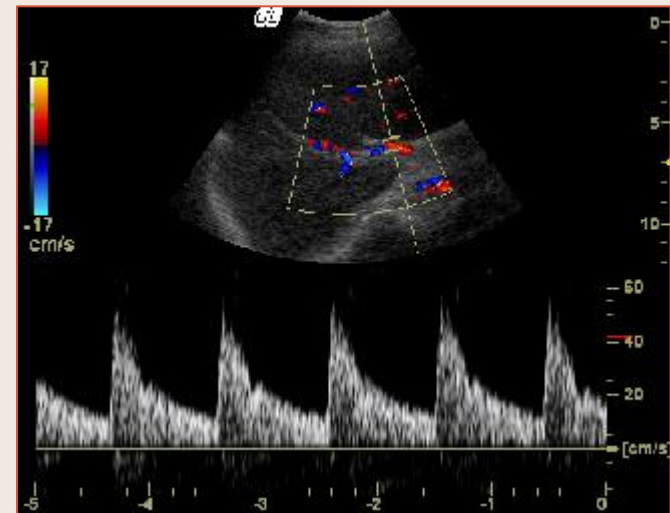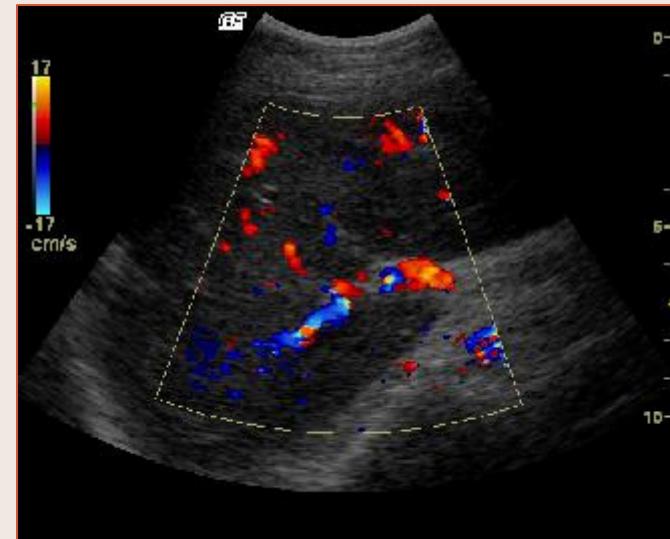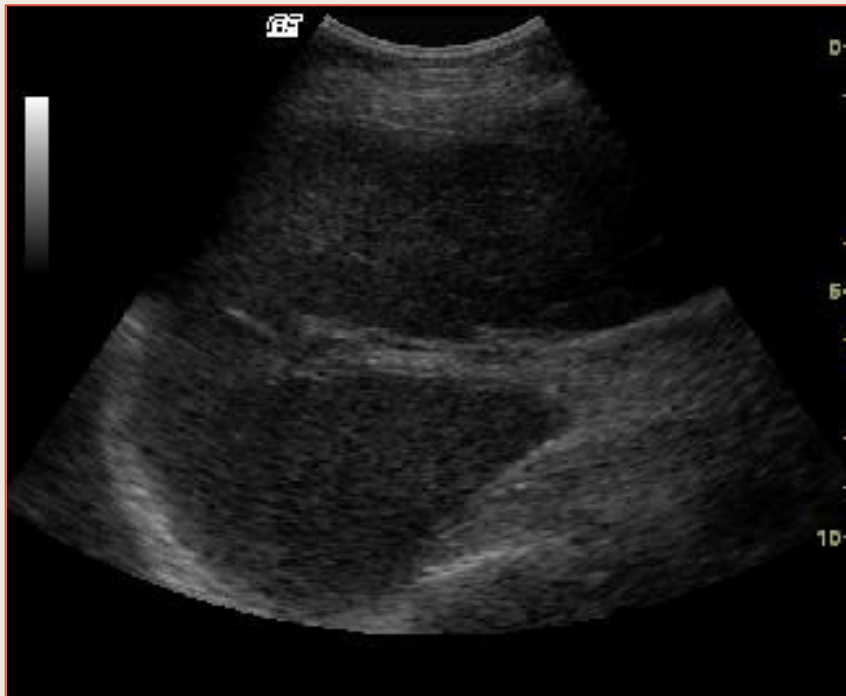
Cavernome portal après thrombose sur polycythémie

Thrombose Veineuse Portale



Cavernome portal après thrombose sur polycythémie

Thrombose Veineuse Portale

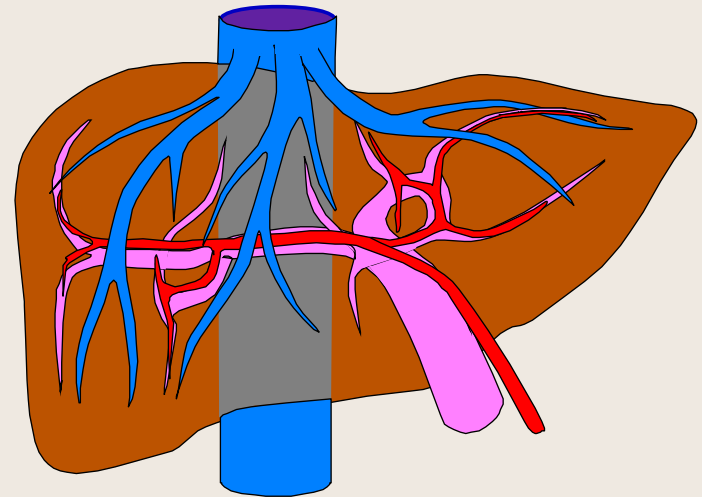


Thrombose veineuse portale + 3 ans

Thrombose de l'artère Hépatique

(cf. Transplant Hépatique)

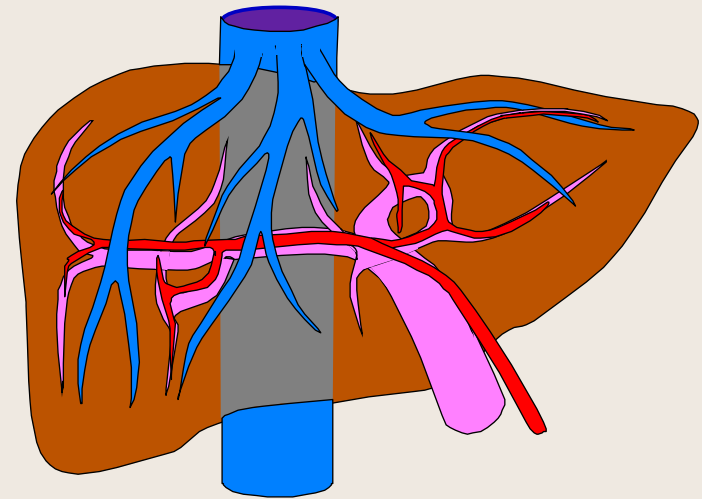
- Signes directs
- Signes indirects
- Pièges du diagnostic



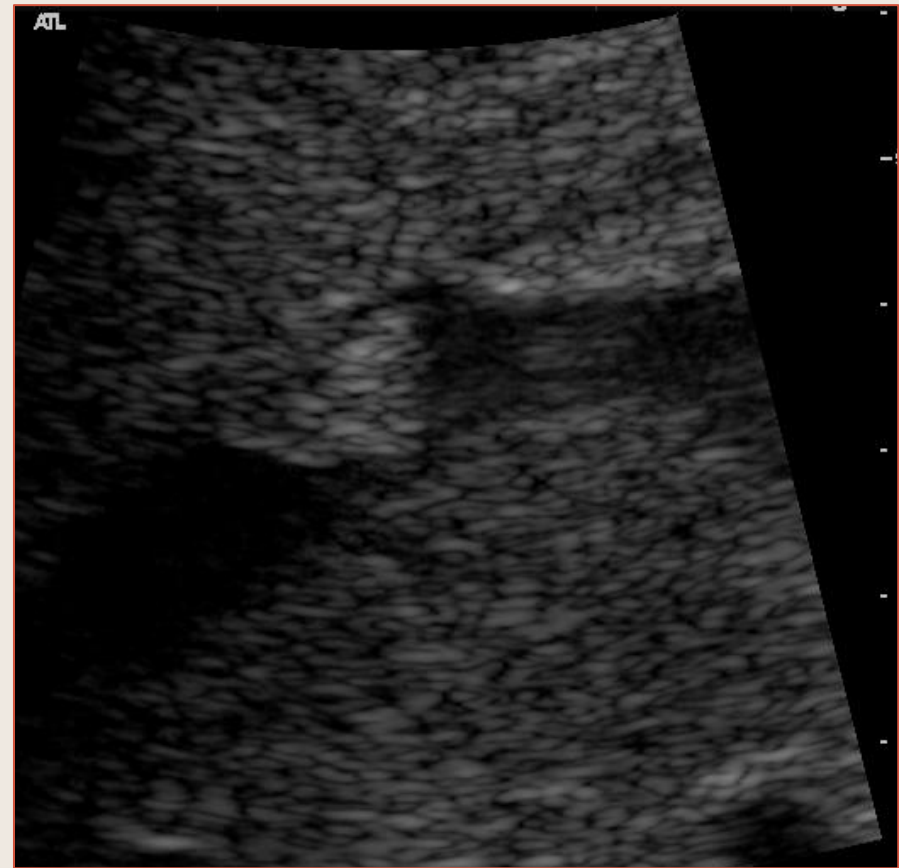
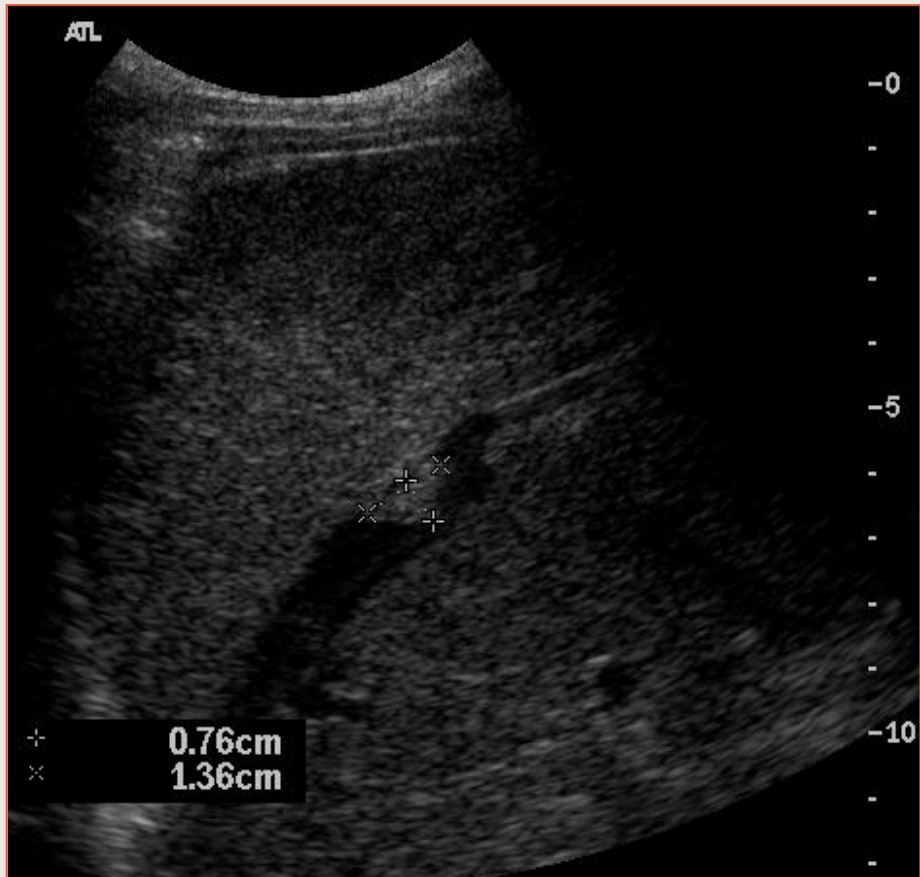Thrombose des Veines Hépatiques

(Syndrome de Budd-Chiari)

- Totale
- Partielle
- Signes directs
- Signes indirects
 - Parenchyme hépatique
 - Flux Veineux Portal



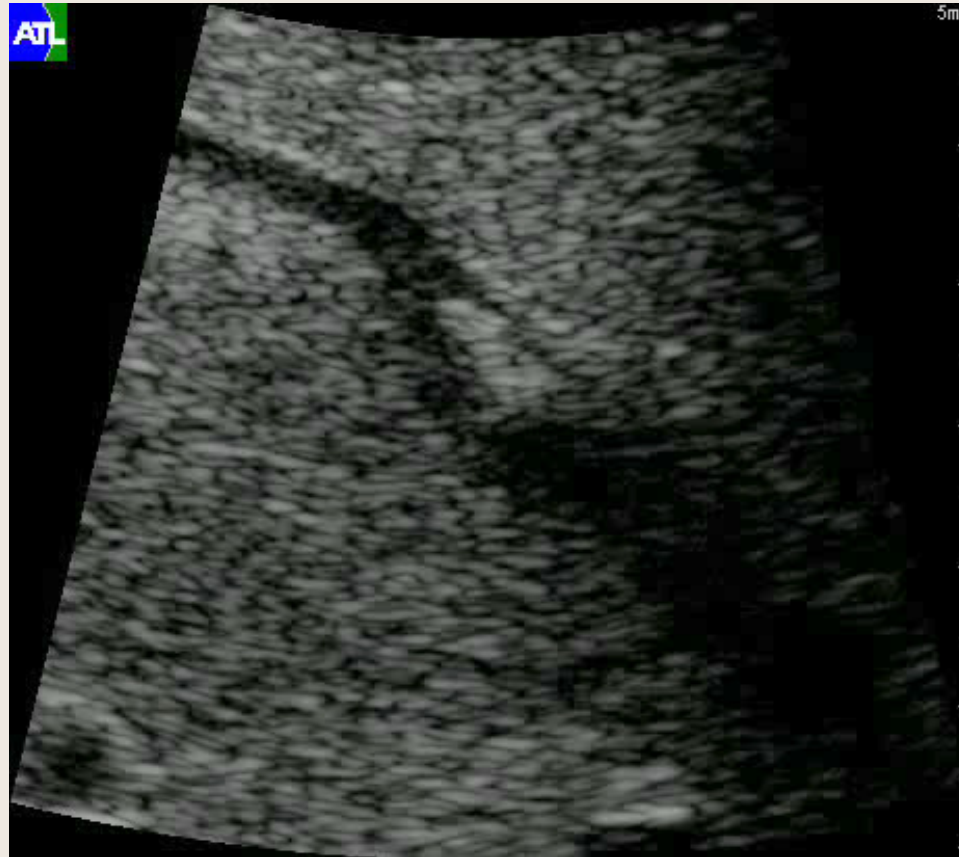Thrombose des Veines Hépatiques



Syndrome de Budd-Chiarri :

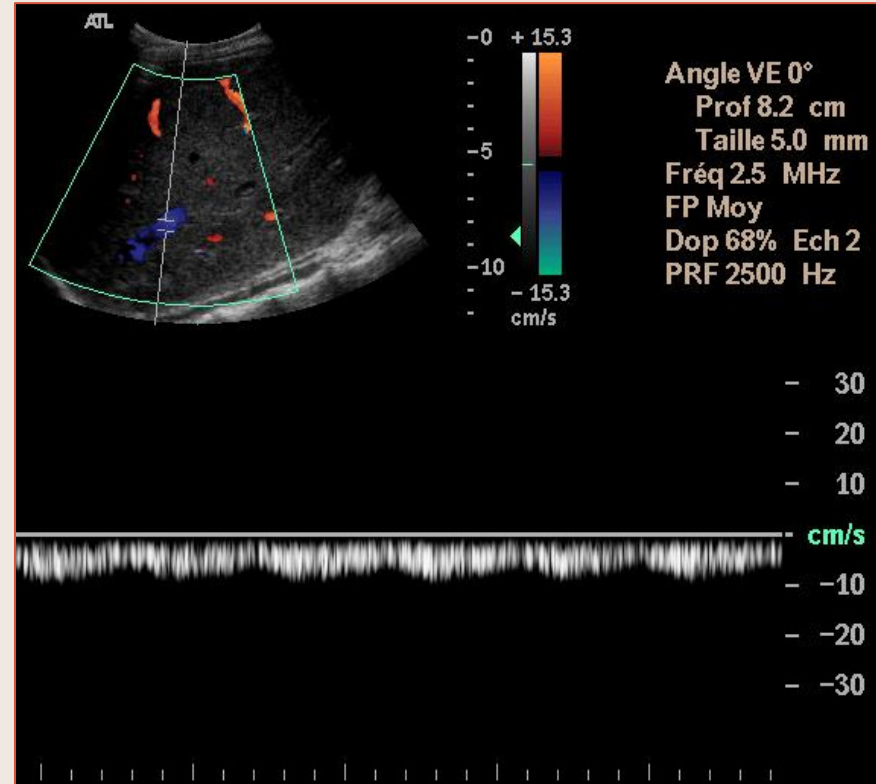
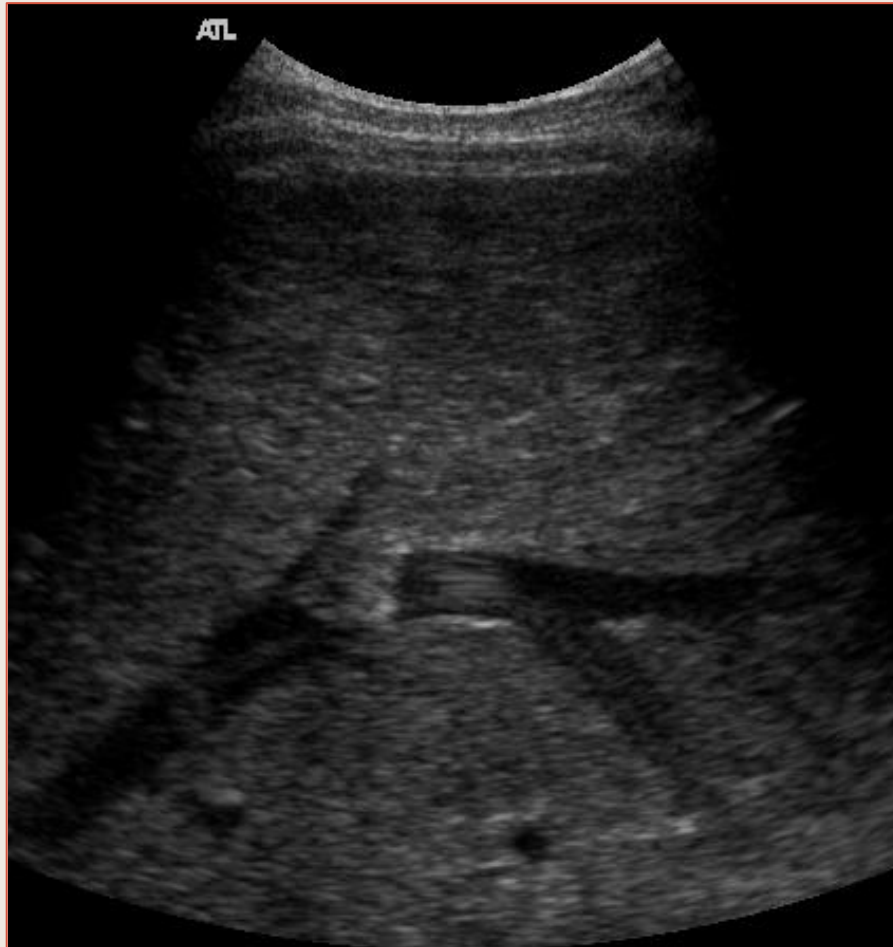Thrombus partiel de la veine hépatique droite – F 24 ans \ pillule

Thrombose des Veines Hépatiques



Syndrome de Budd-Chiari :
Thrombus partiel de la veine hépatique droite

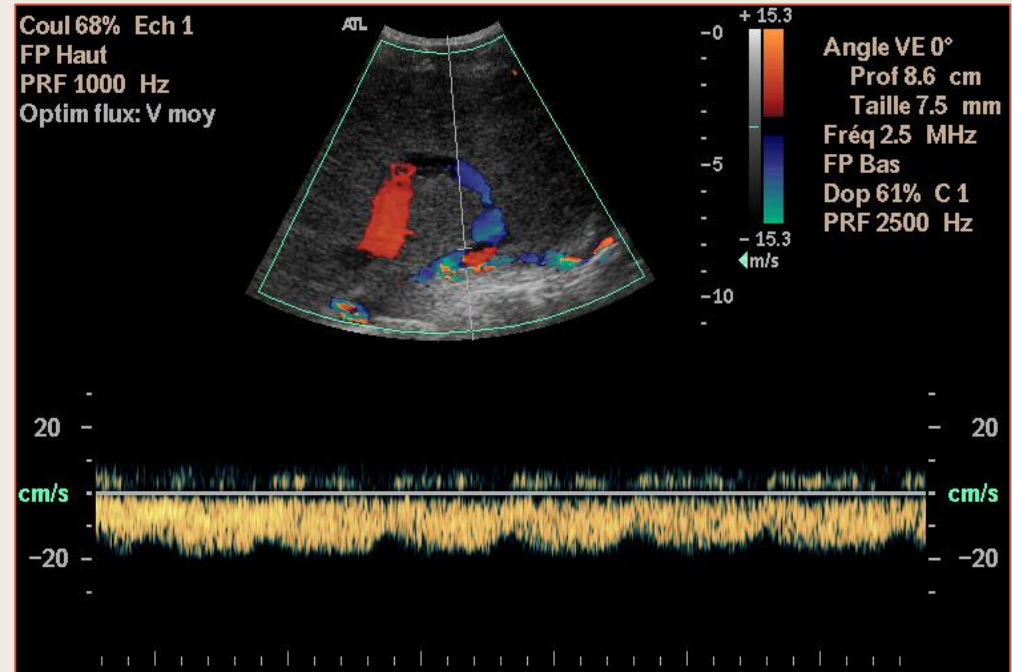
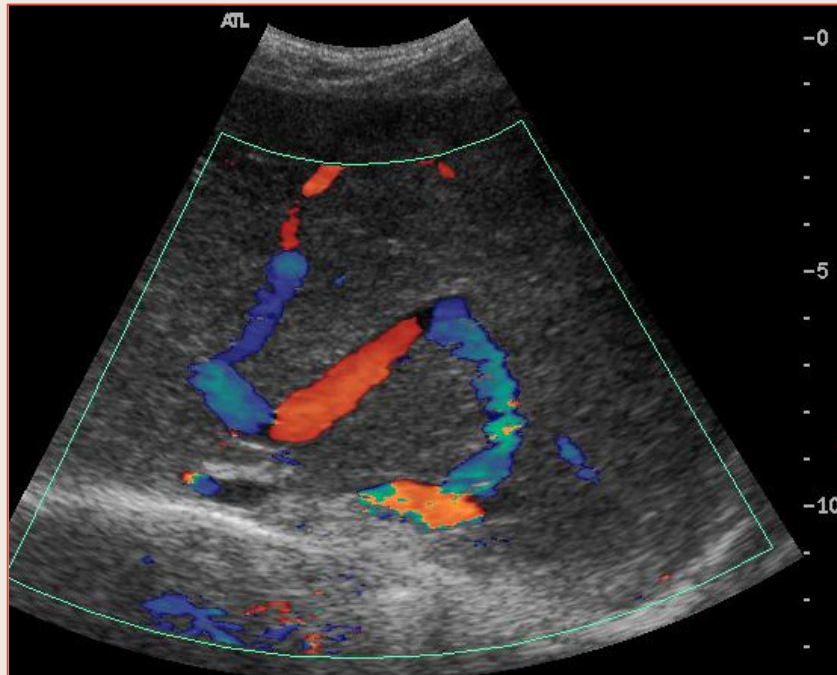
Thrombose des Veines Hépatiques



Syndrome de
Budd-Chiarri :

Thrombus partiel de la veine hépatique droite

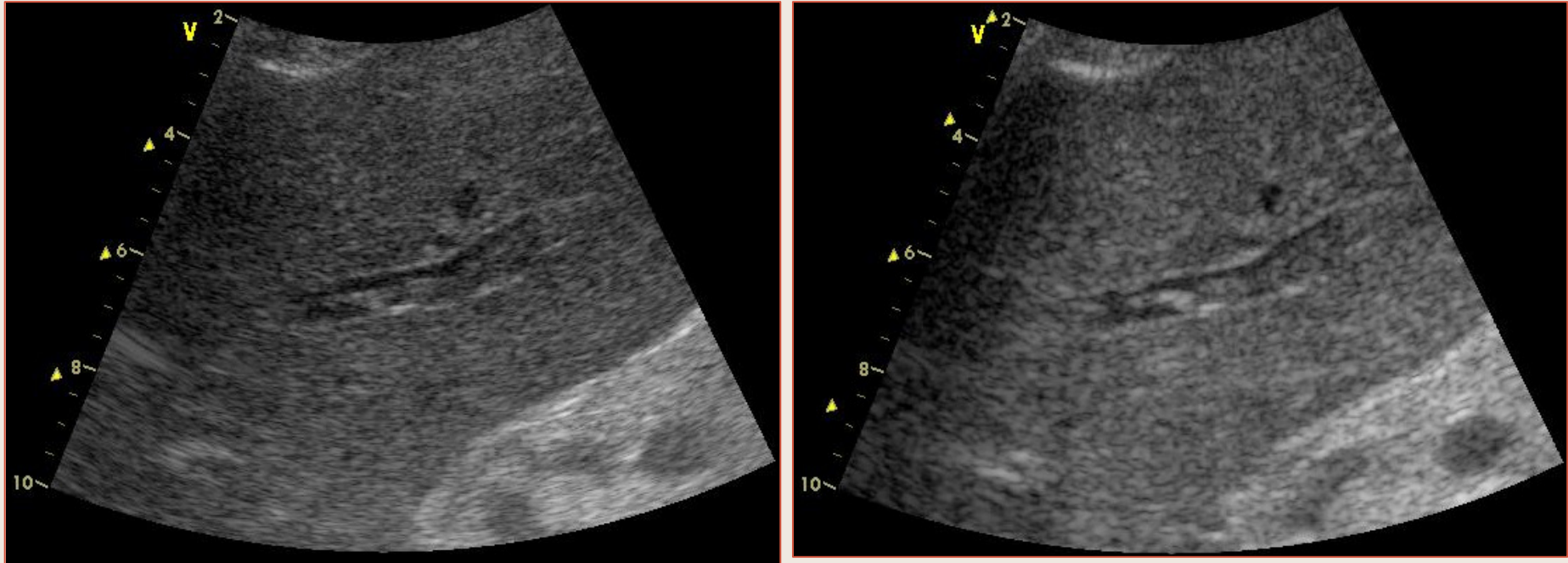
Thrombose des Veines Hépatiques



Syndrome de Budd-Chiari :

Collatérale Veine Hépatique médiane – Veine Hépatique gauche

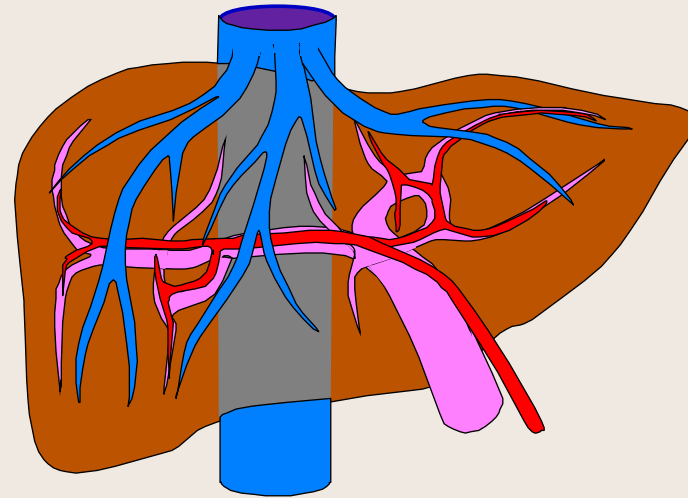
Thrombose des Veines Hépatiques



Syndrome de Budd-Chiarri :
Thrombose de la veine hépatique gauche (syndrome myéloprolifératif)

Hypertension Portale

- **Pré-Hépatique**
- **Hépatique**
 - Pré-sinusoïdale
 - Sinusoïdale
 - Post-Sinusoïdale

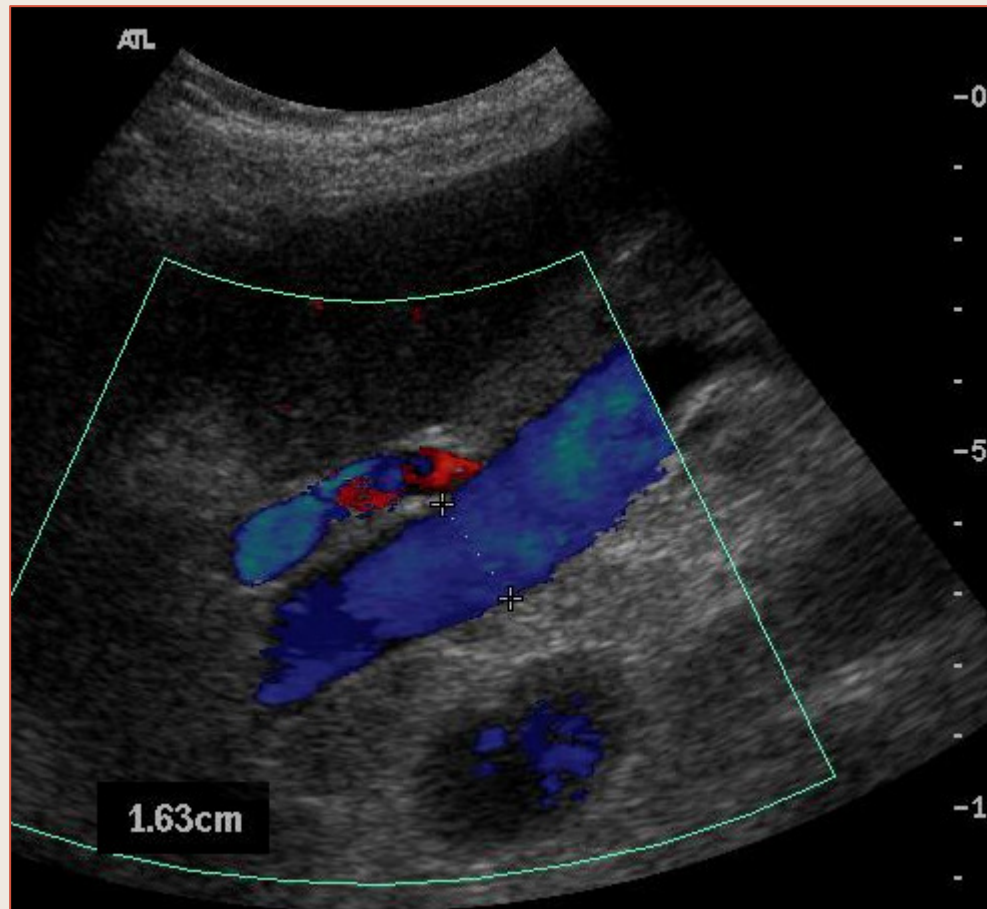


- **Cirrhotique**
- **Idiopathique**
- **Par hyperdébit**

Hypertension Portale

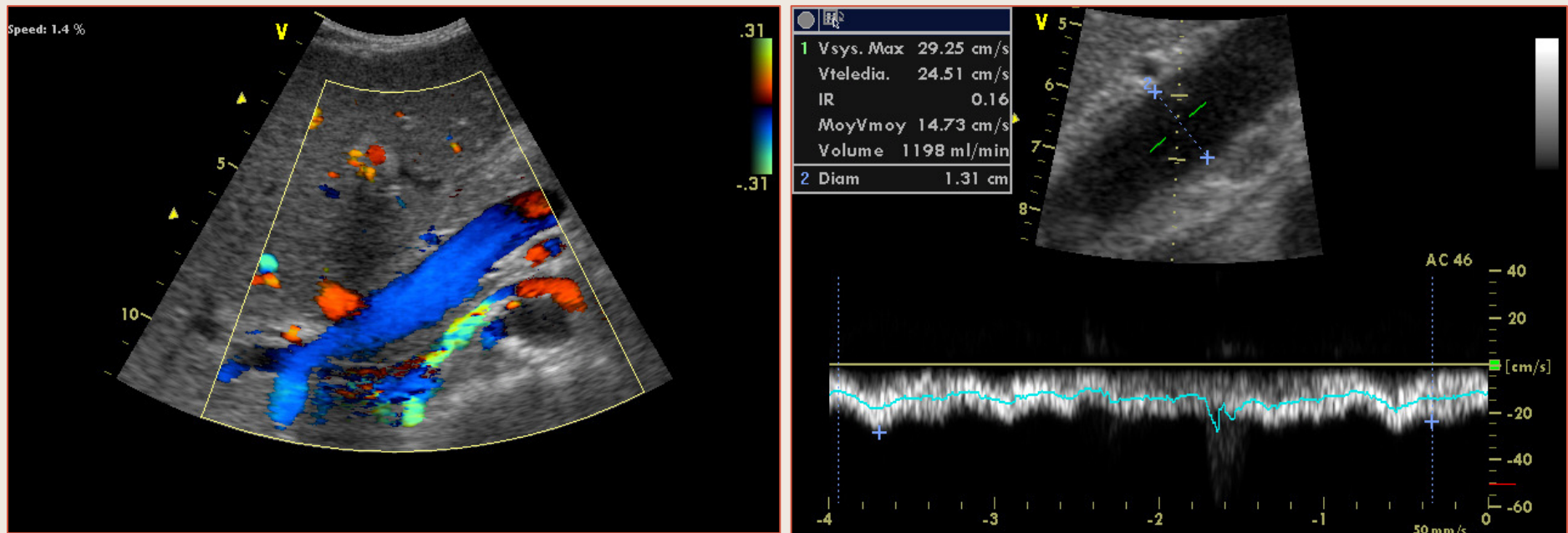
- Bons “Vrais signes”
 - Indice de “congestion hépatique”
 - Altération des variations de diamètre
- Bons “Faux signes”
 - Diamètre de la veine porte
 - Collatérales intra et/ou extra-hépatiques
 - Inversion circulatoire intra et/ou extra-hépatique
 - Démodulation du flux veineux hépatique
- Autres signes
 - Débit portal
 - Modulation du flux portal

Hypertension Portale



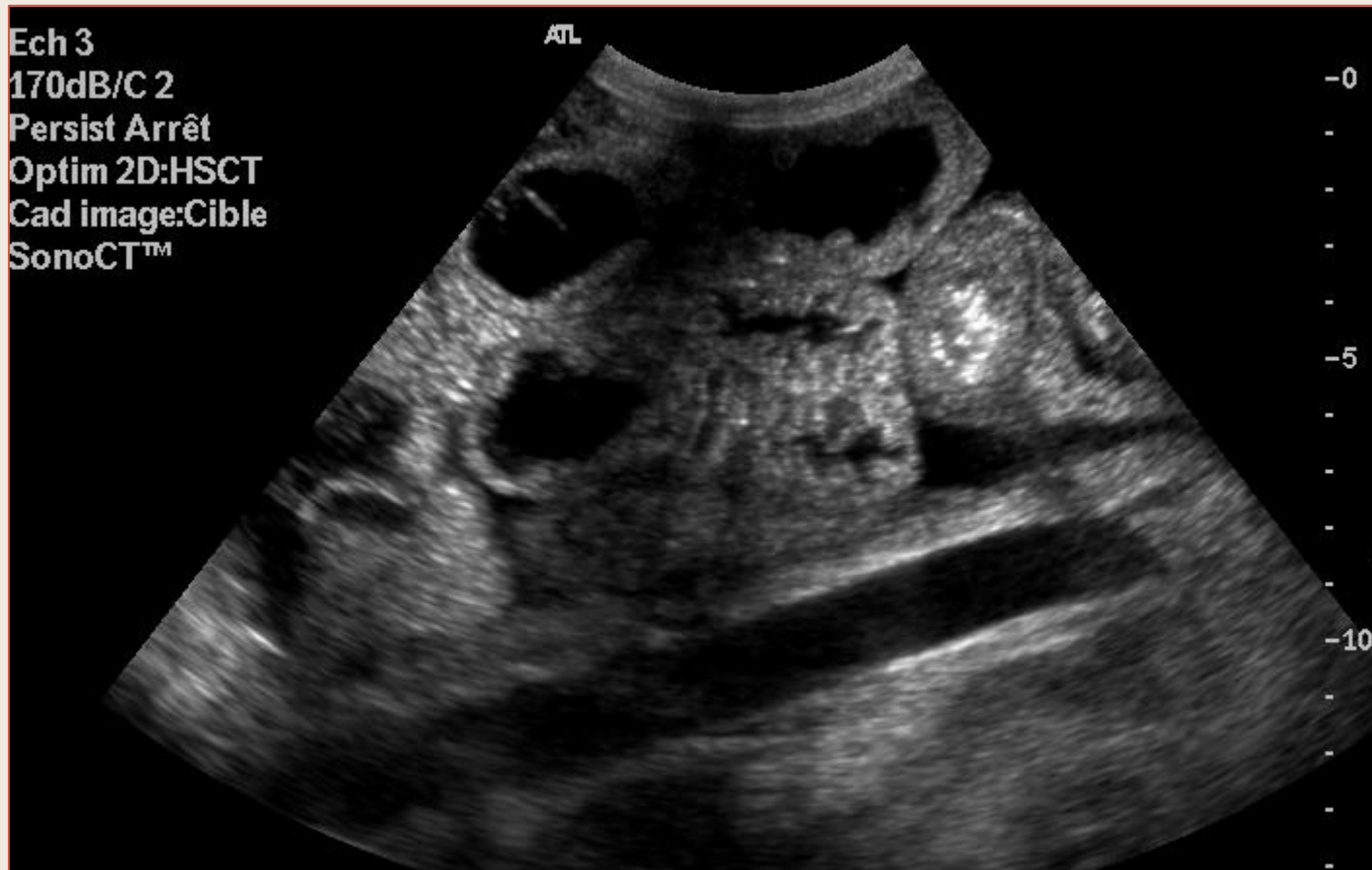Cirrhose – Veine Porte large

Hypertension Portale



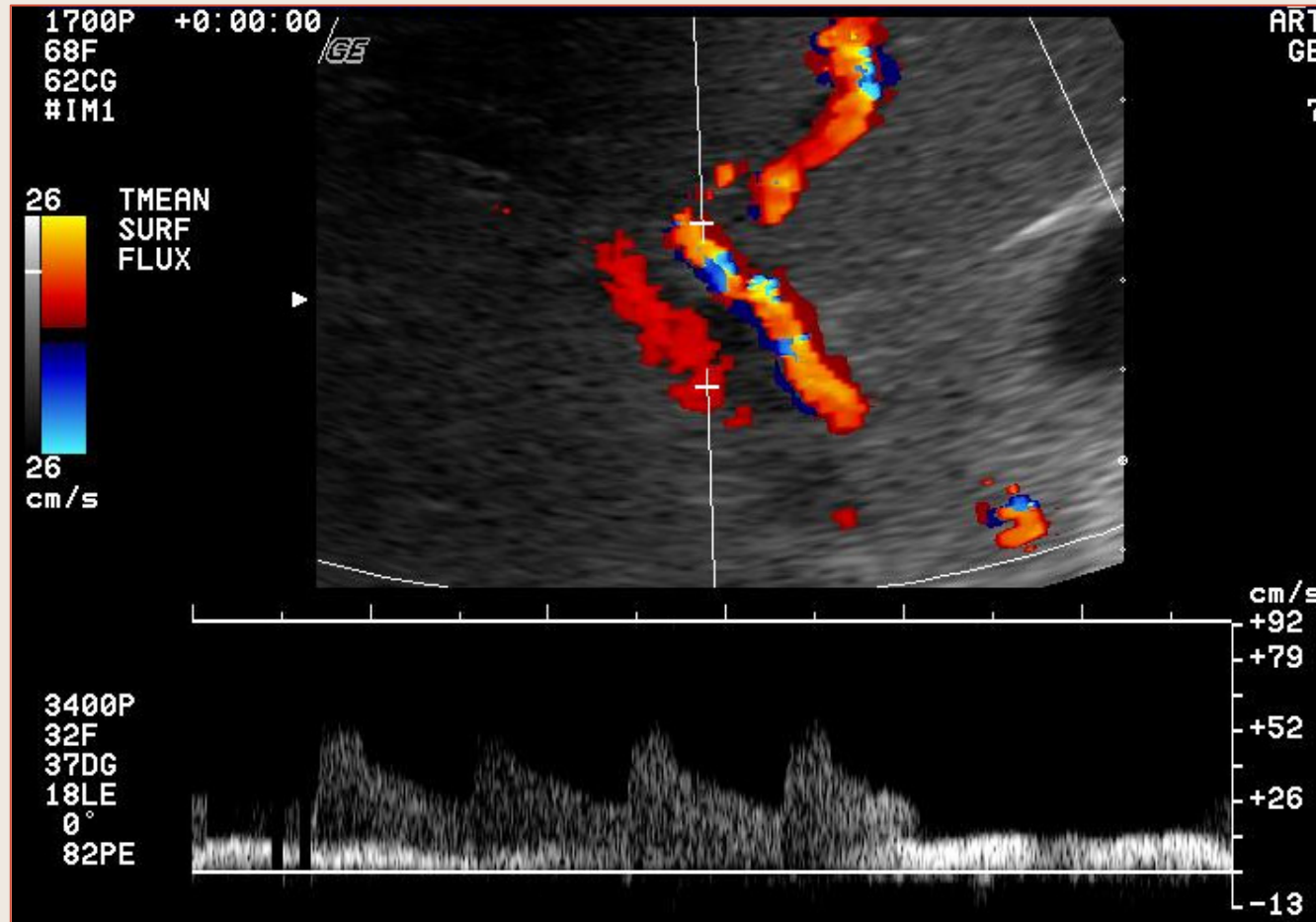
Hyperdynamie Splanchnique

Hypertension Portale



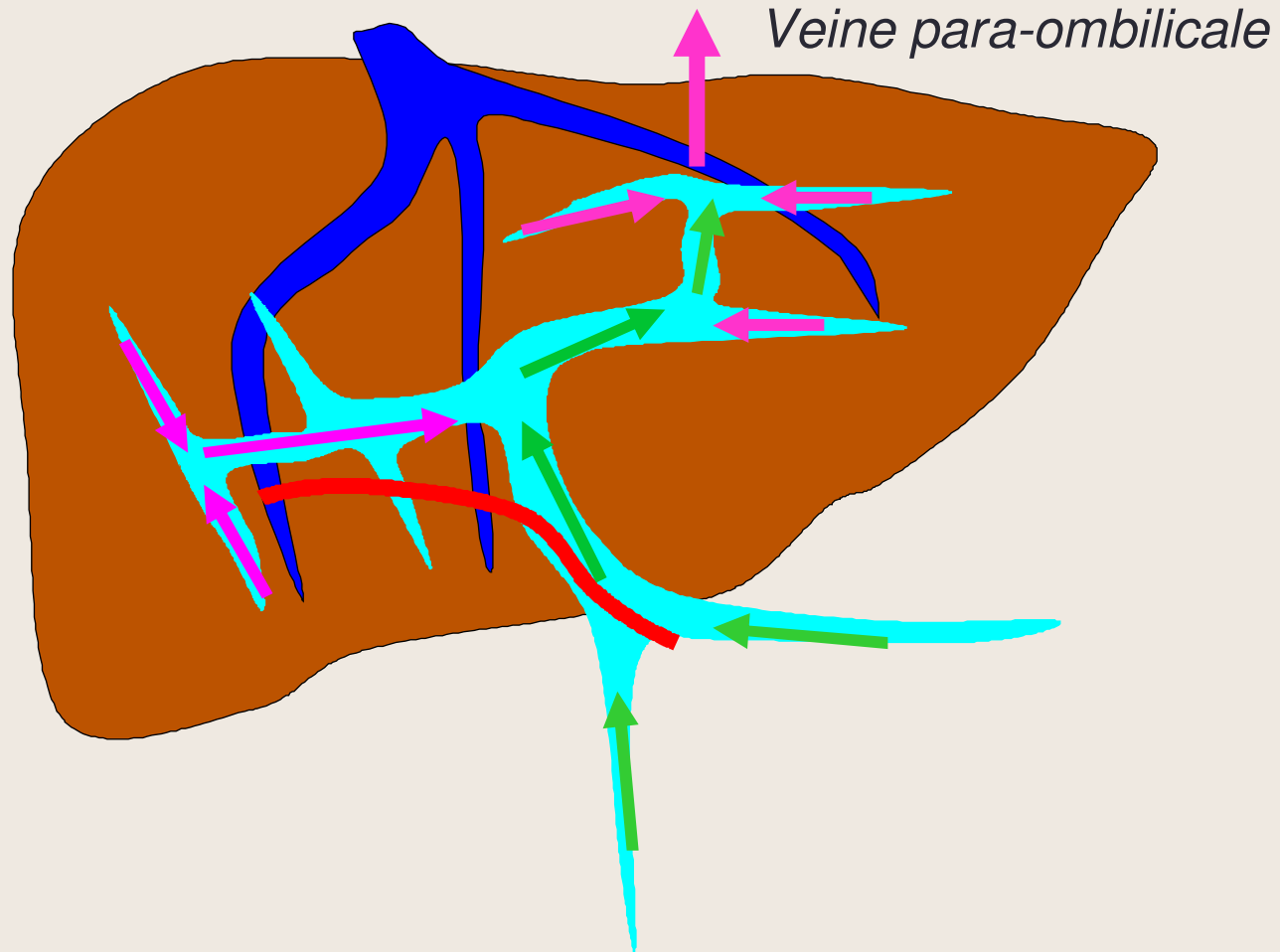
Ascite

Hypertension Portale



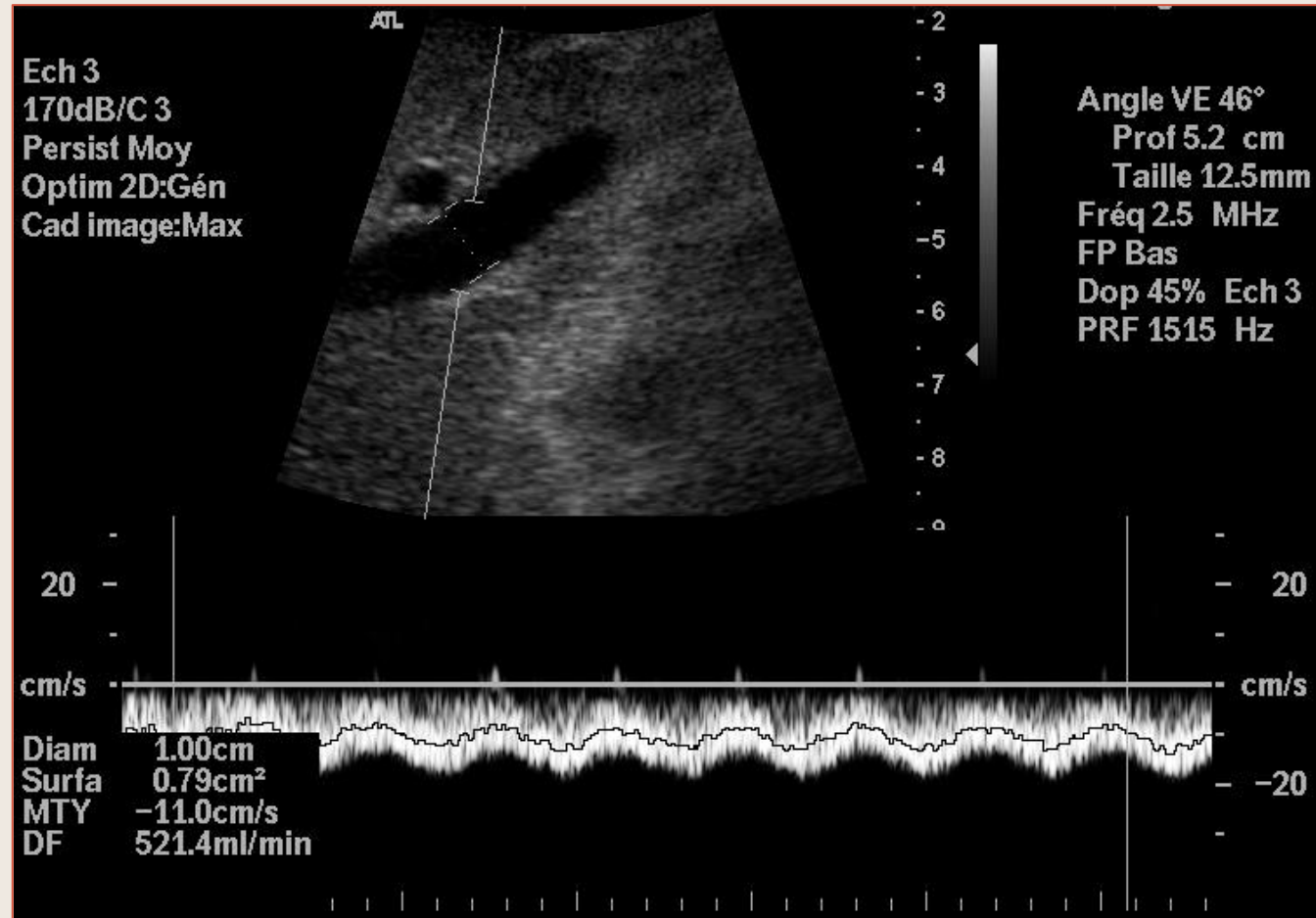
Cirrhose – Flux portal intra-hépatique (VP gauche) de sens normal

Hypertension Portale



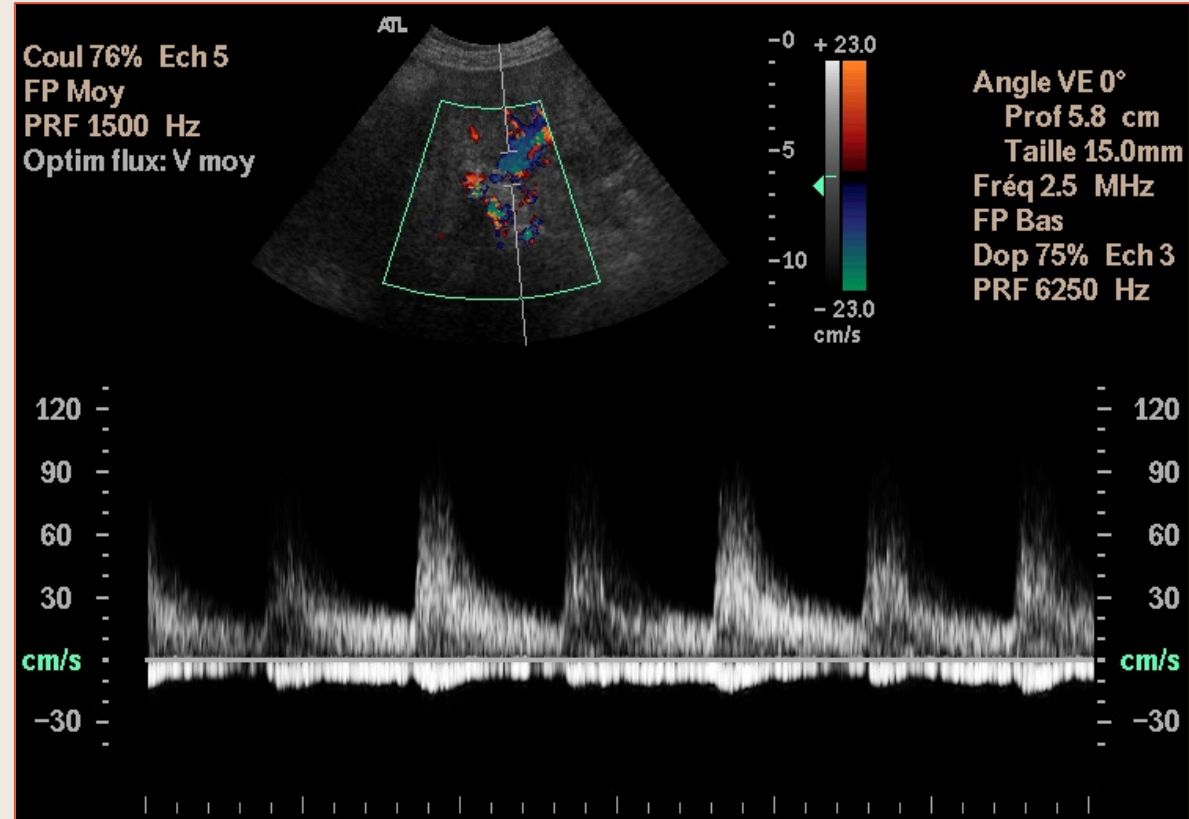
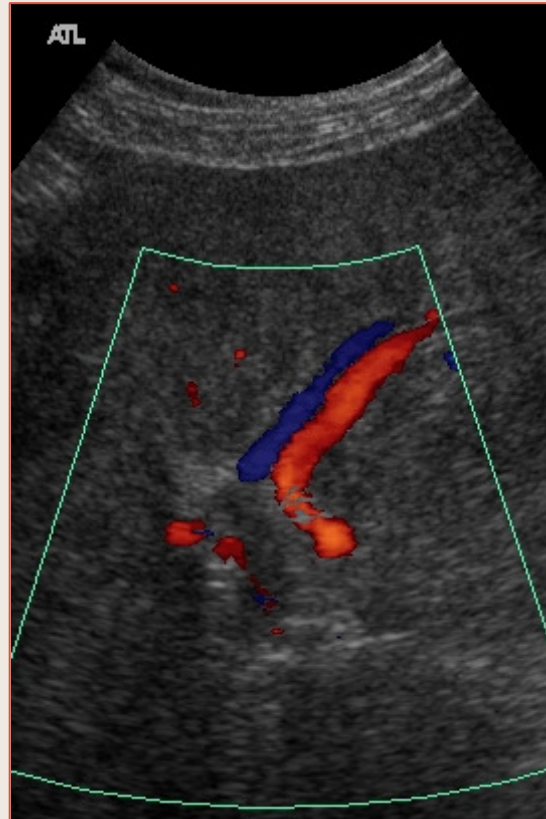
Inversion circulatoire portale intra-hépatique globale et veine para-ombilicale hépatofuge

Hypertension Portale



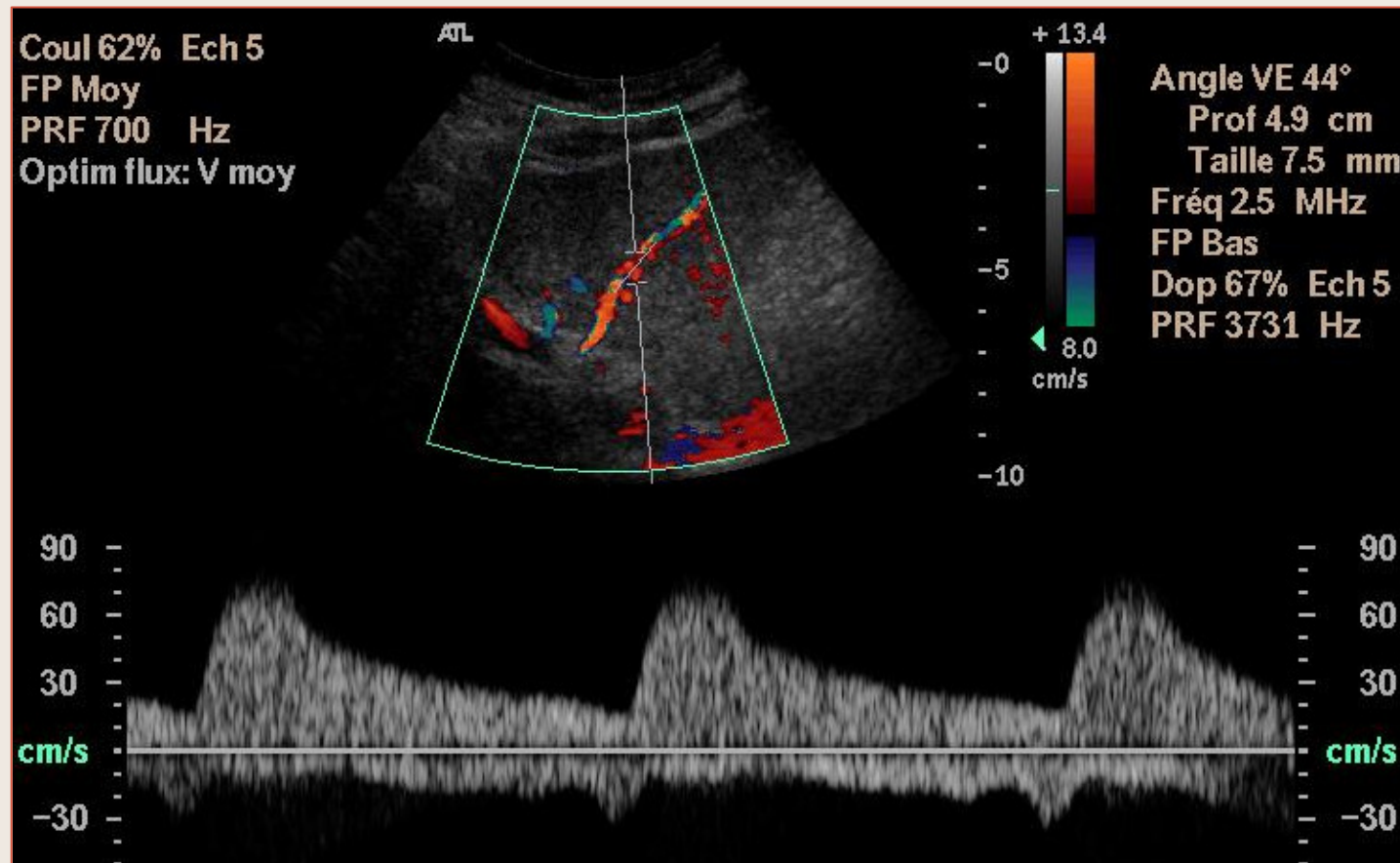
Sens circulatoire normal et débit correct dans le tronc porte

Hypertension Portale



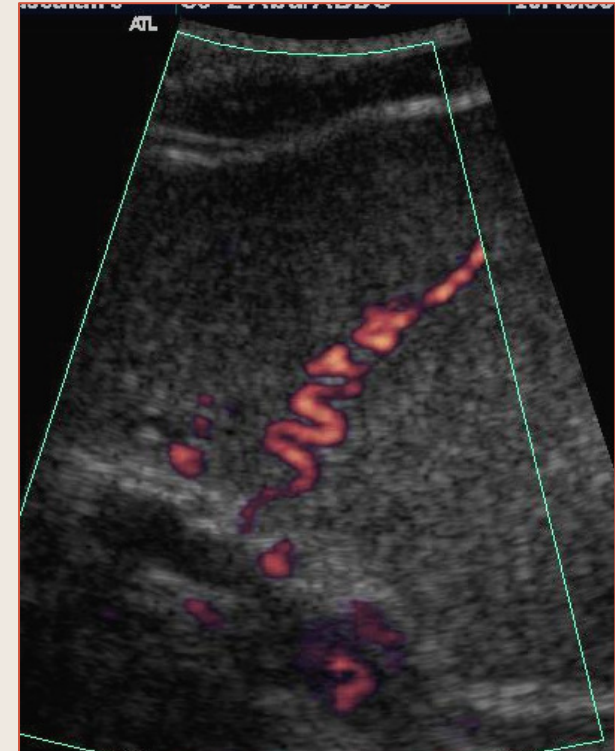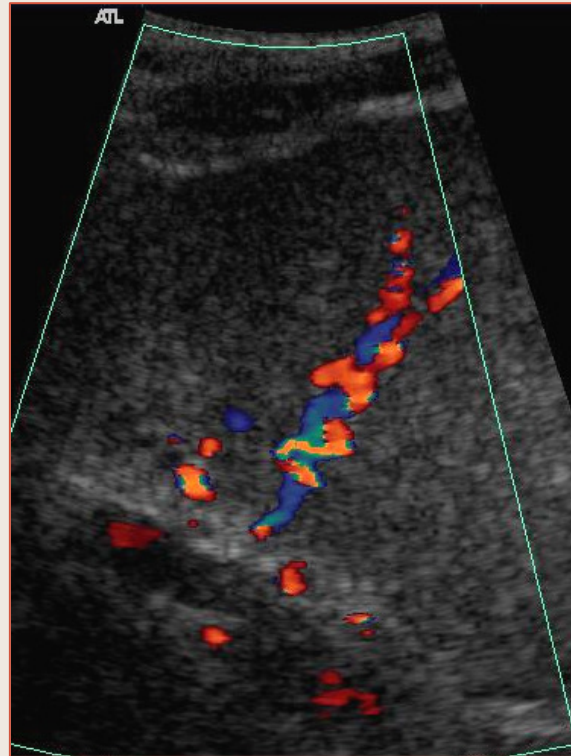
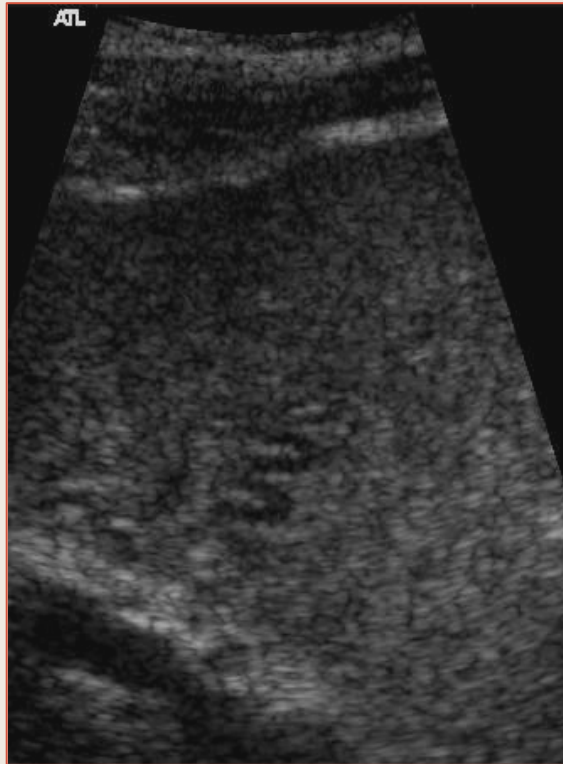
Inversion circulatoire portale dans le foie gauche

Hypertension Portale



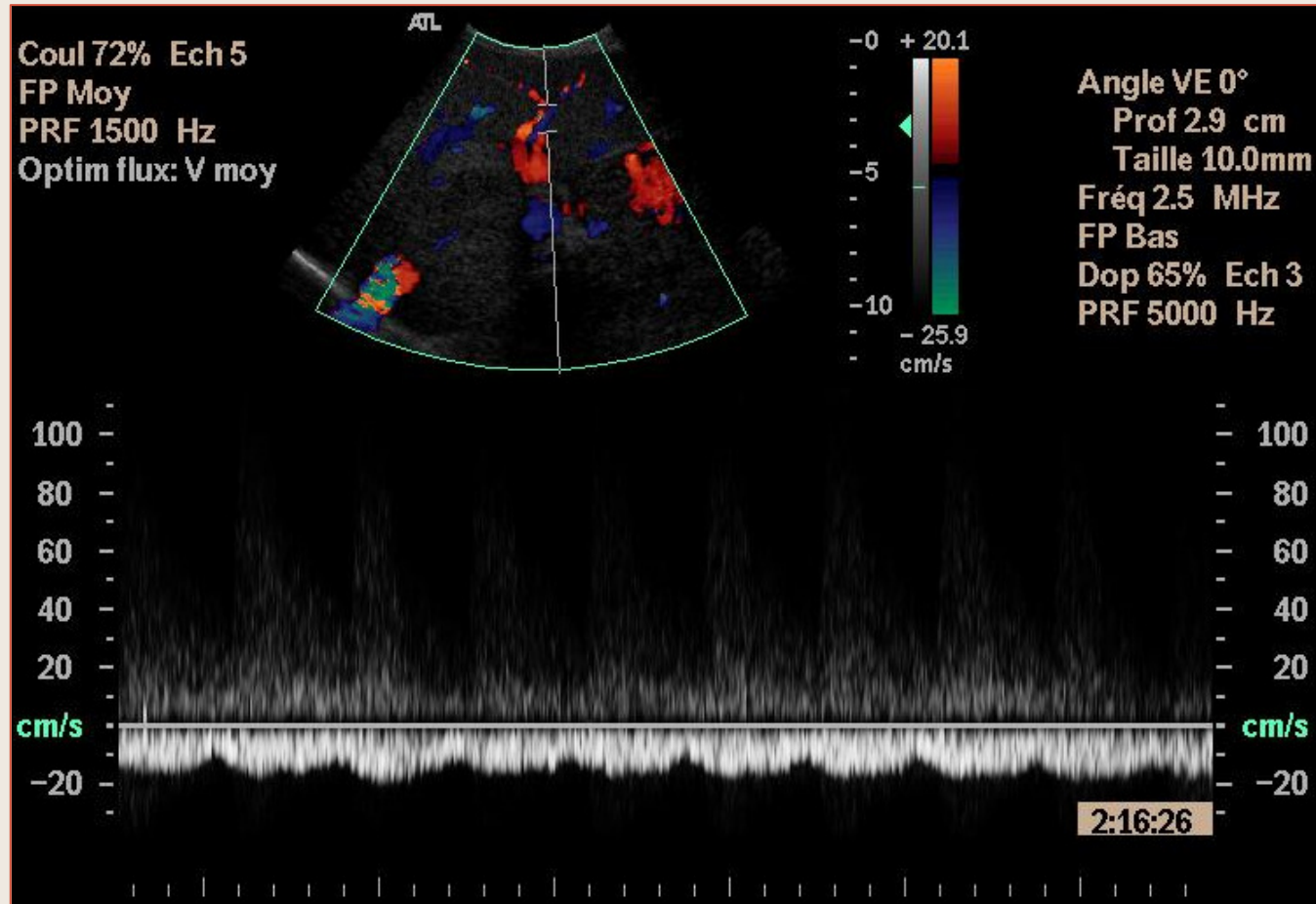
Inversion circulatoire portale dans le foie gauche avec artère hépatique tortueuse

Hypertension Portale



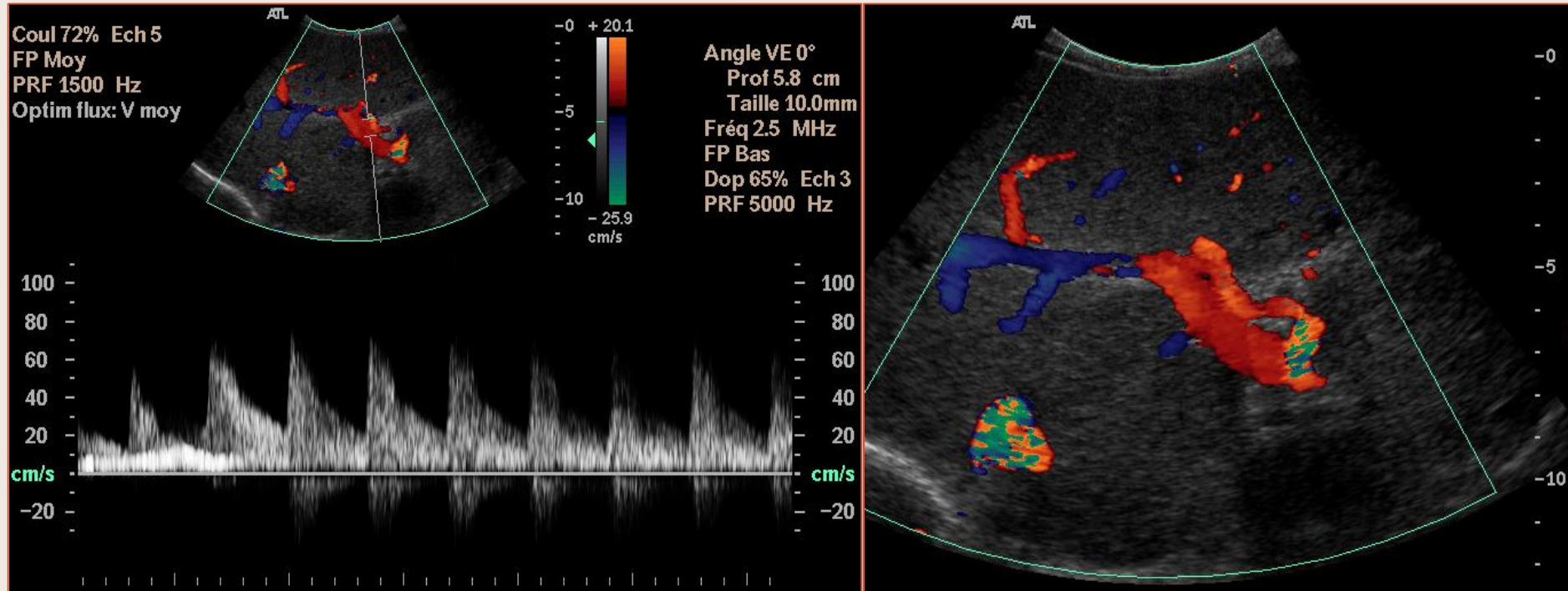
Inversion circulatoire portale dans le foie gauche
avec artère hépatique tortueuse

Hypertension Portale



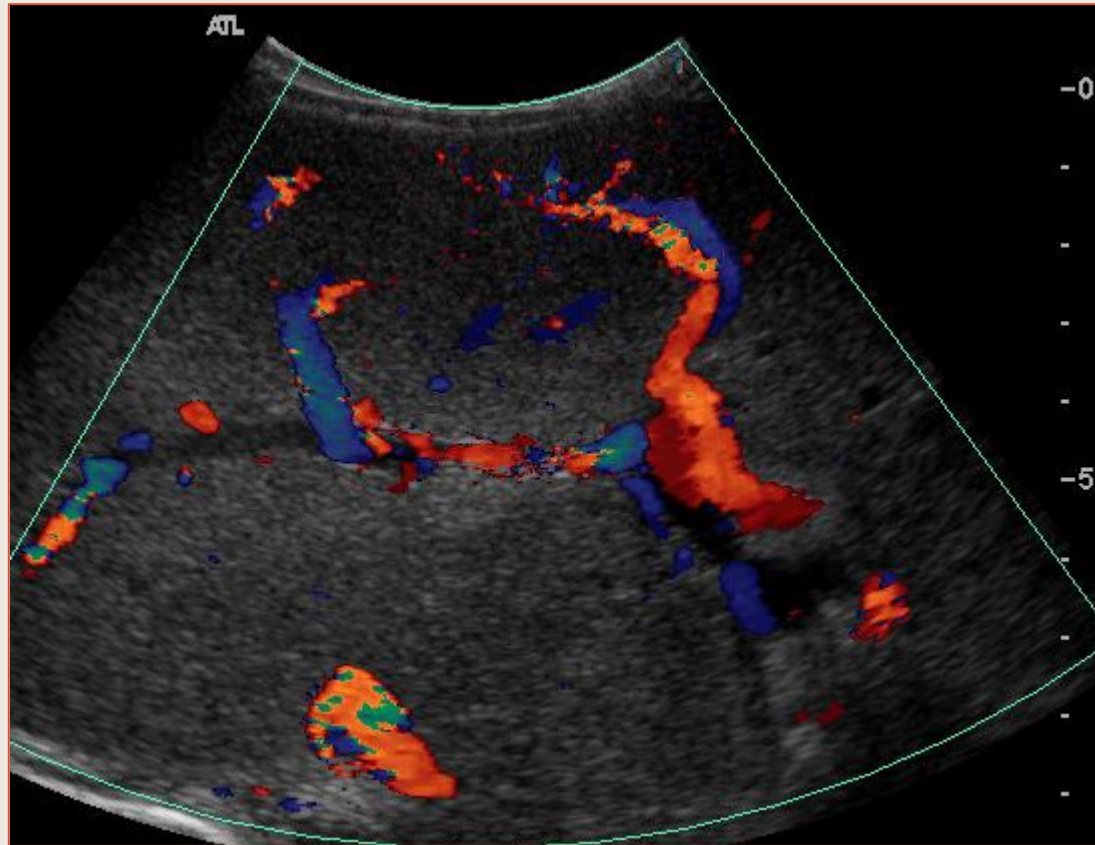
Inversion Circulatoire Portale dans le Foie gauche

Hypertension Portale



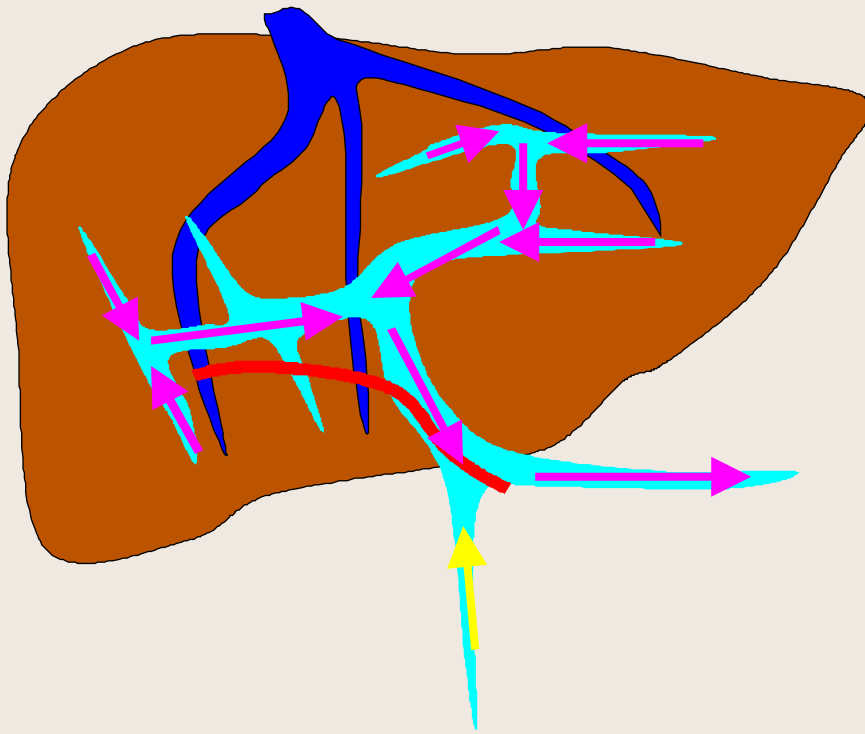Sens circulatoire normal dans le foie droit

Hypertension Portale

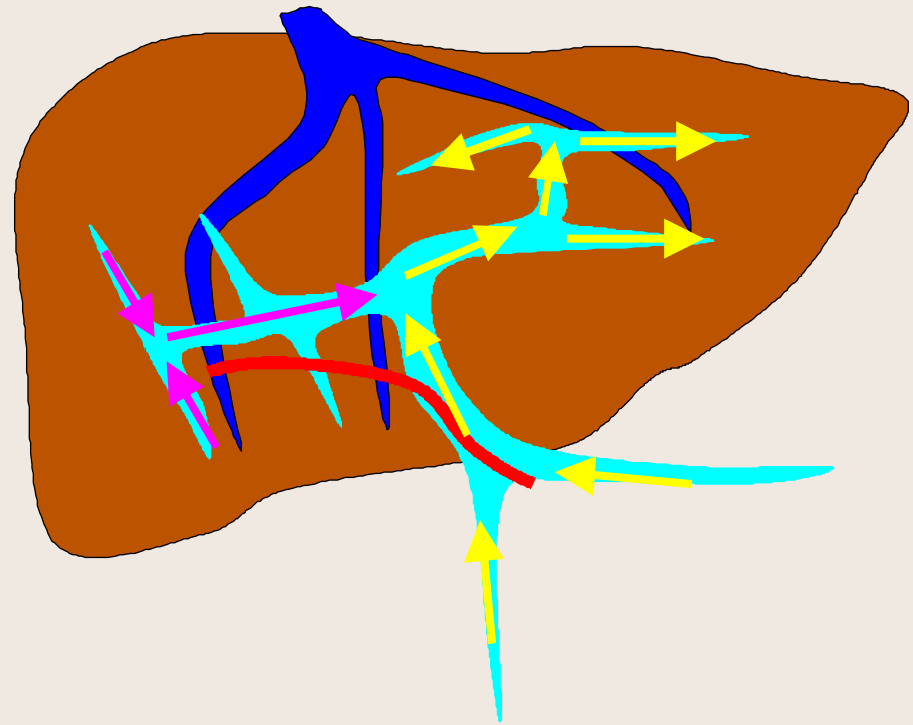

Inversion Circulatoire Portale dans le Foie droit

Hypertension Portale

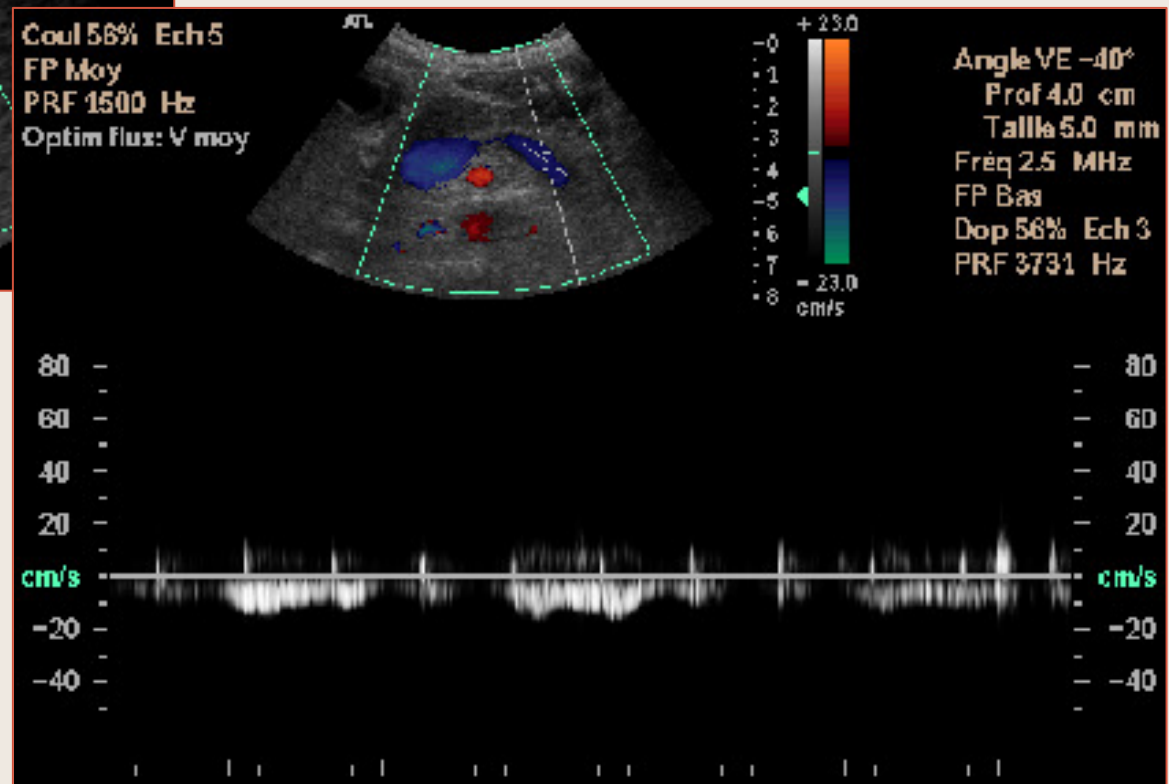
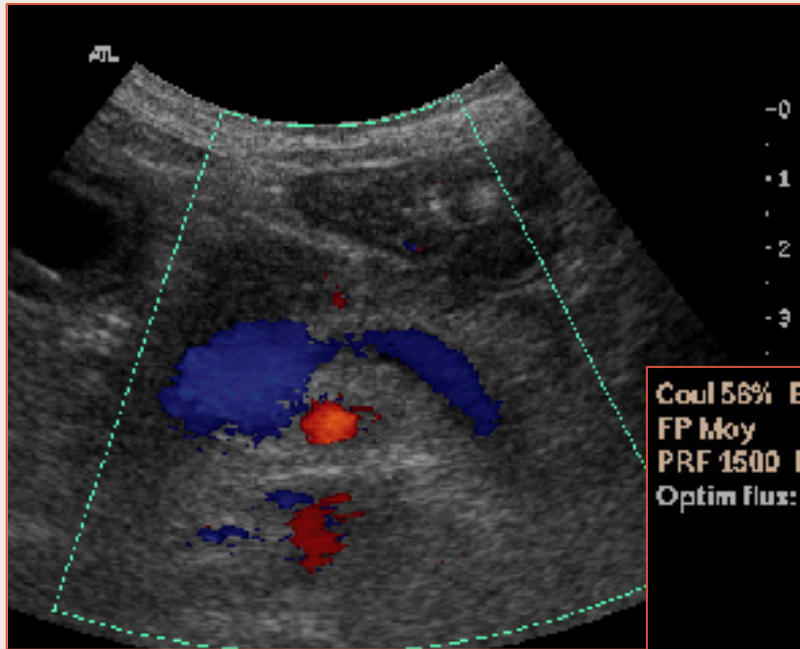


Inversion circulatoire portale intra-hépatique et extra-hépatiques avec shunts spléno-rénaux



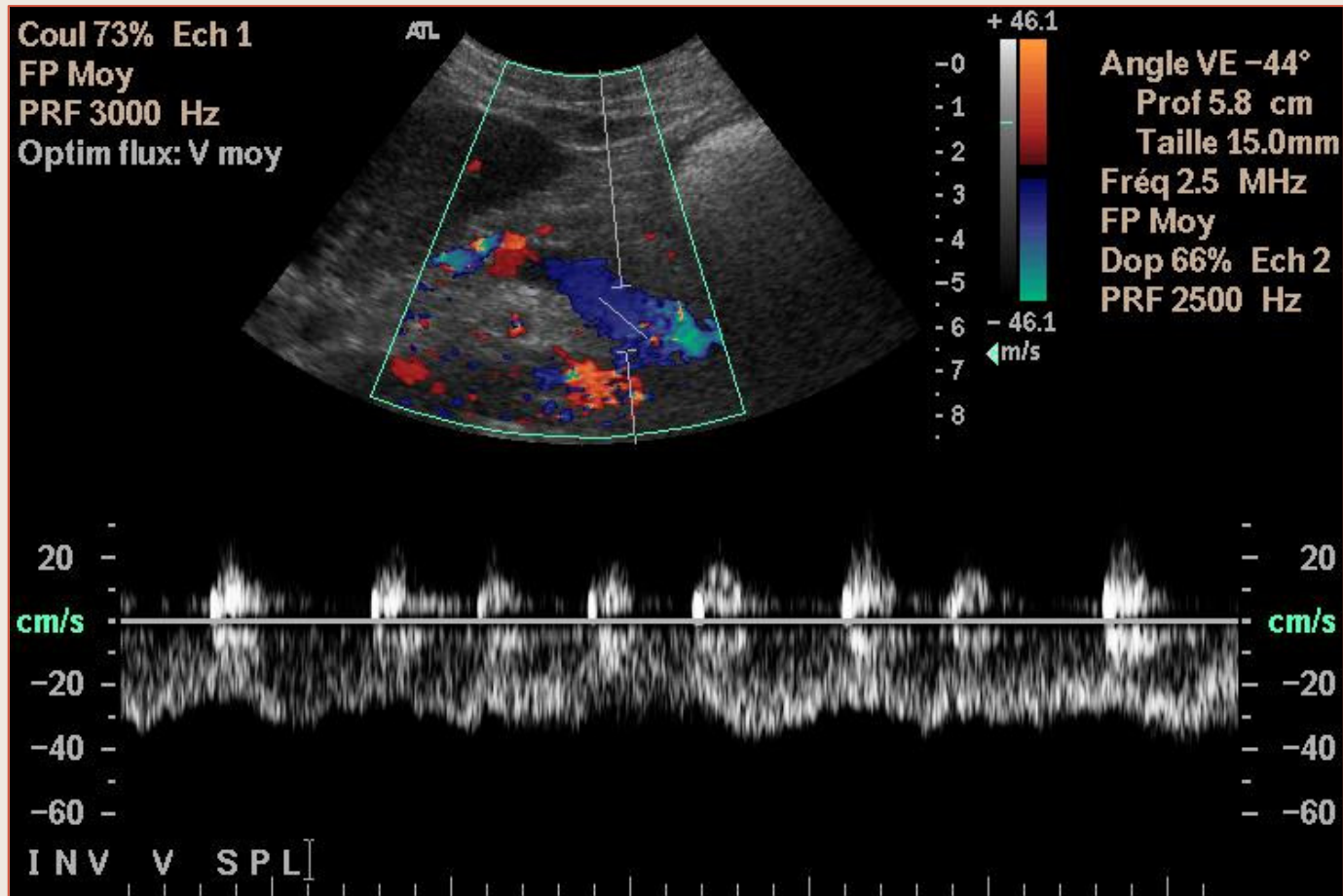
Inversion circulatoire portale intra-hépatique partielle (droite)

Hypertension Portale



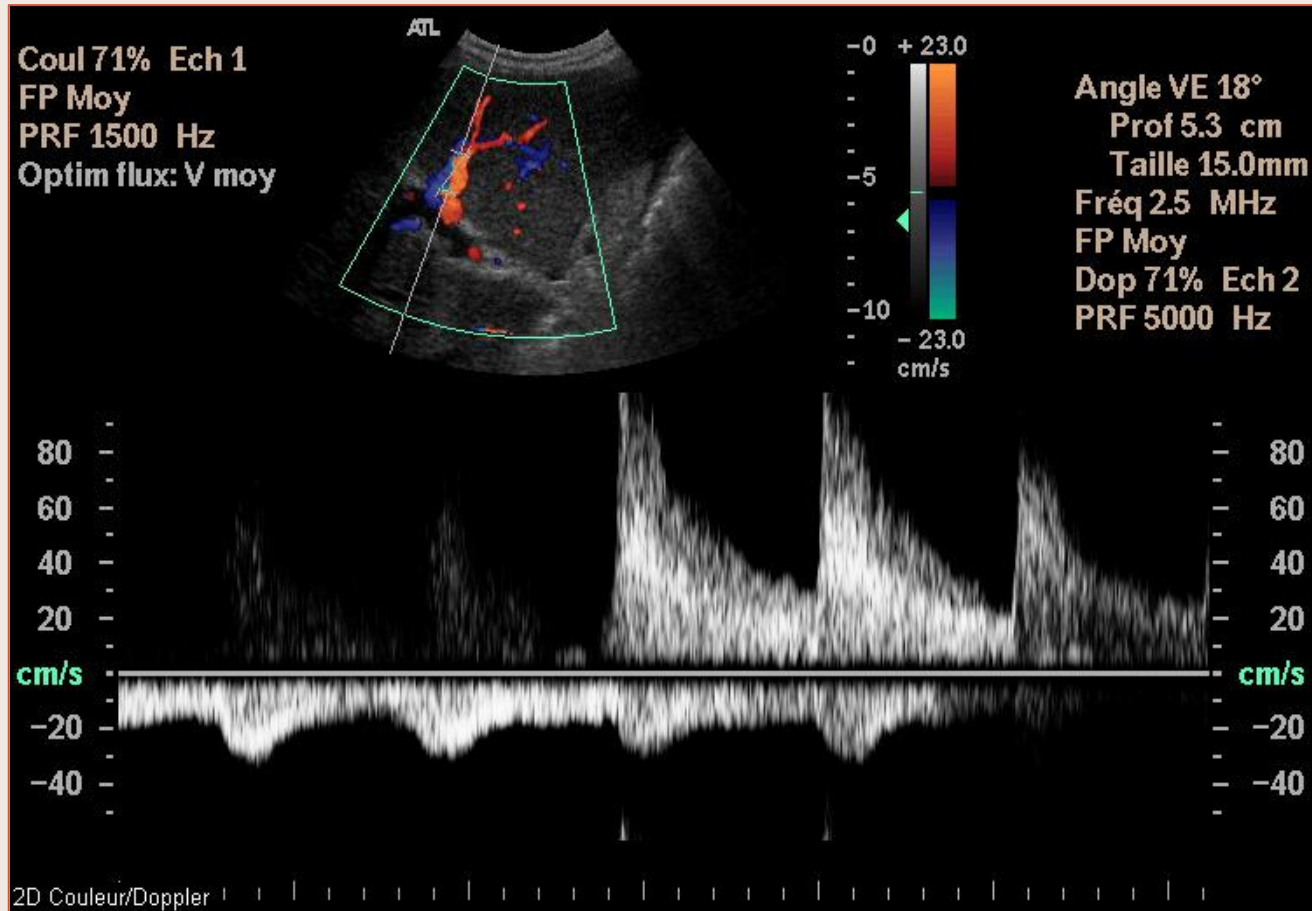
Inversion circulatoire dans la veine splénique

Hypertension Portale



Inversion circulatoire dans la veine splénique

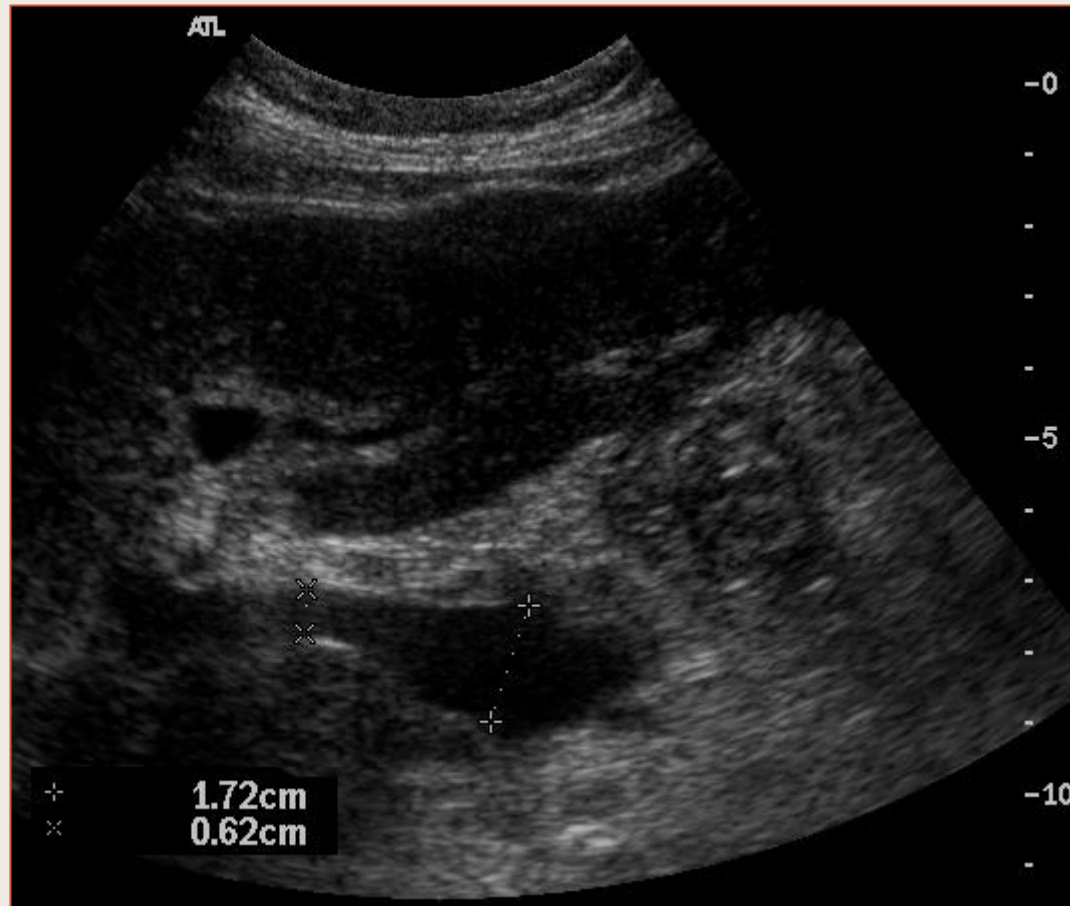Hypertension Portale



Inversion complète :

Hypertension portale, inversion circulatoire portale

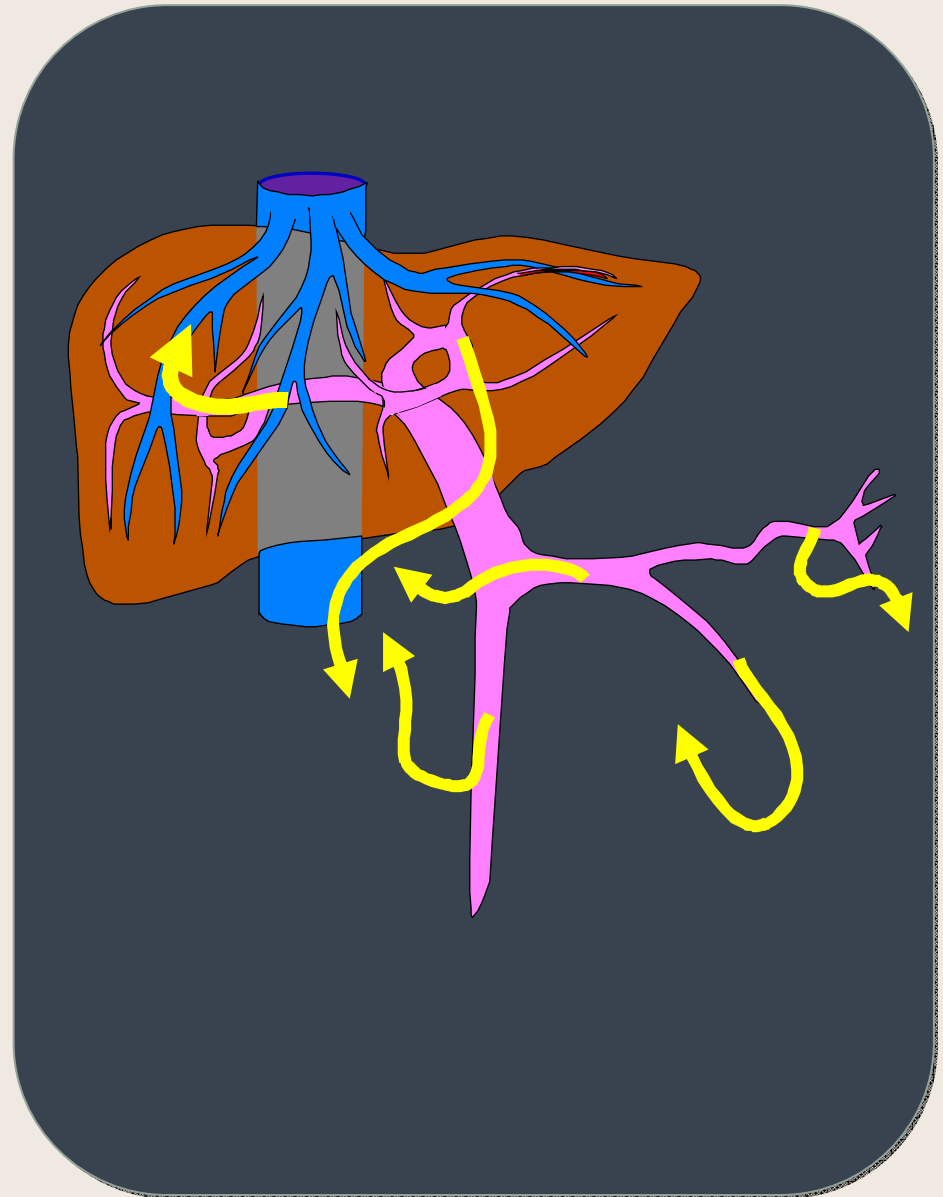
Hypertension Portale



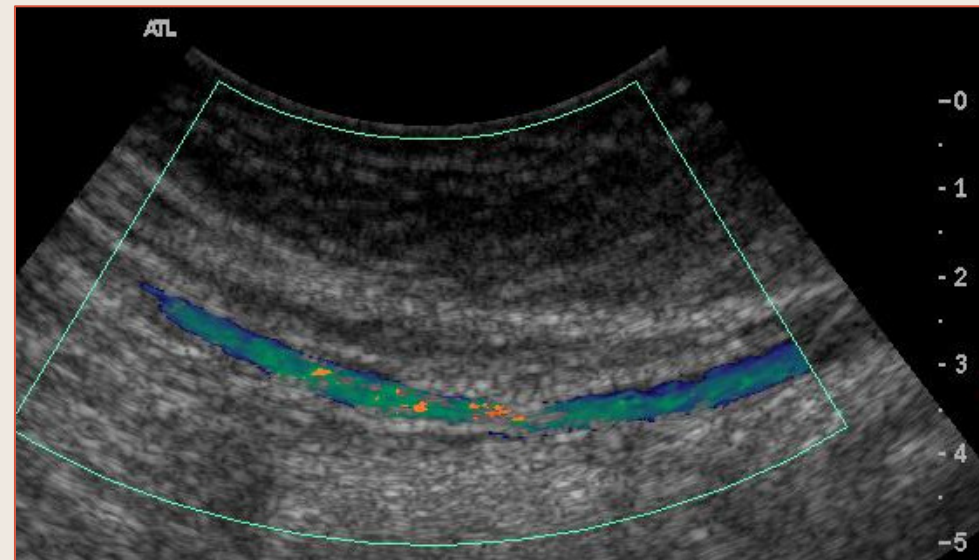
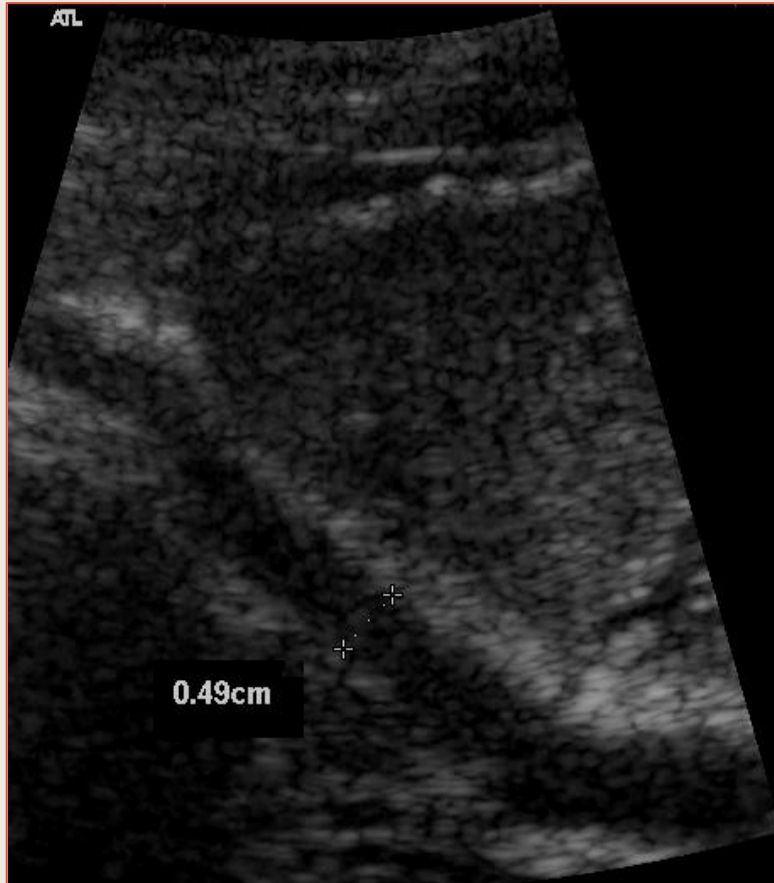
Dilatation du confluent spléno-mésentérique

Collatérales Porto-Systemiques

- Intra-hépatiques
 - Veines Para-Ombilicales
 - Shunts intra-hépatiques spontanés
- Extra-Hépatiques
 - Veine Gastrique Gauche
 - Shunts Spléno-Rénaux spontanés
 - Autres dérivations
- Thérapeutiques
 - Dérivations spléno-rénale, méésentérico-cave, porto-cave...
 - TIPS

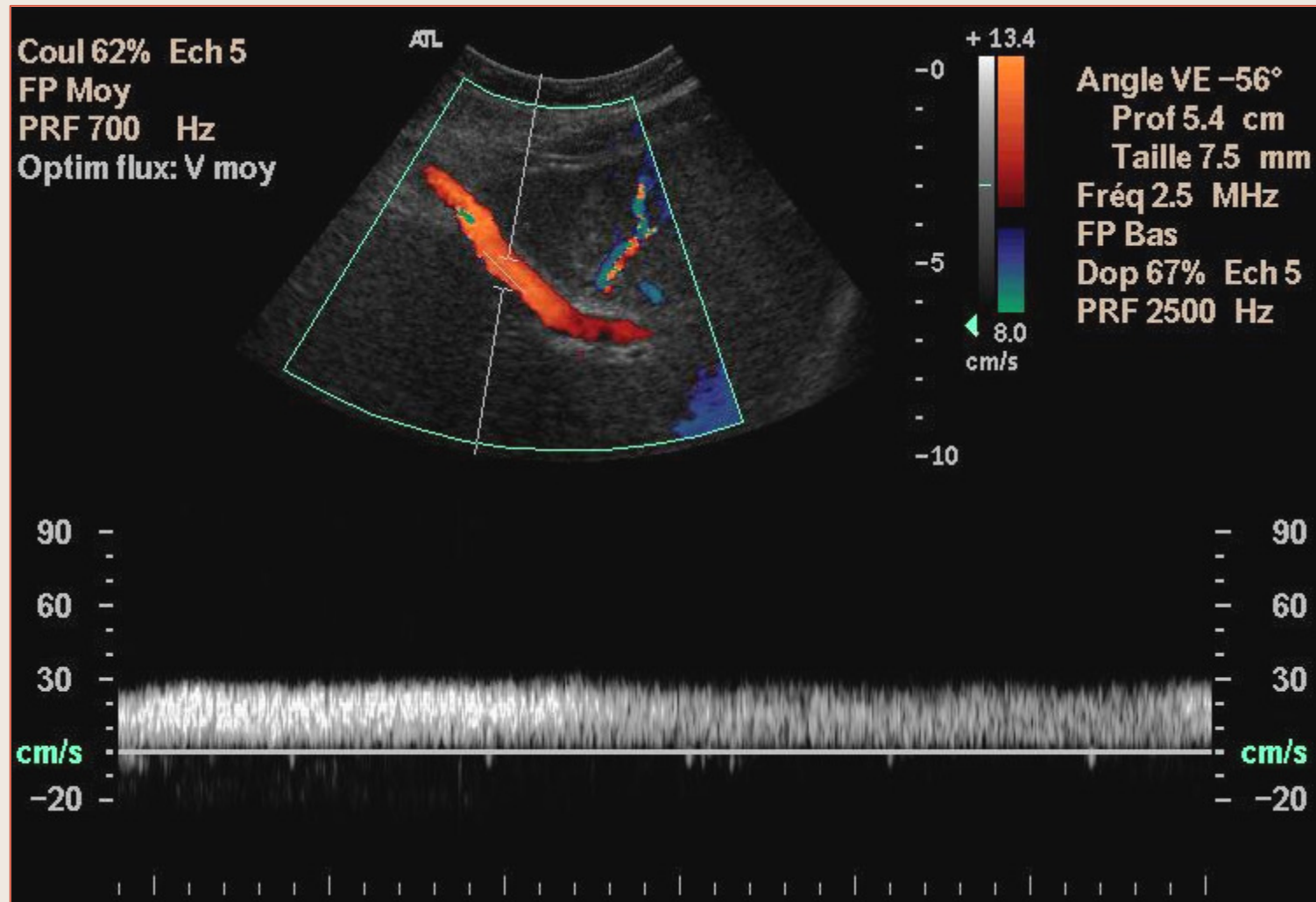


Dérivations Porto-Caves



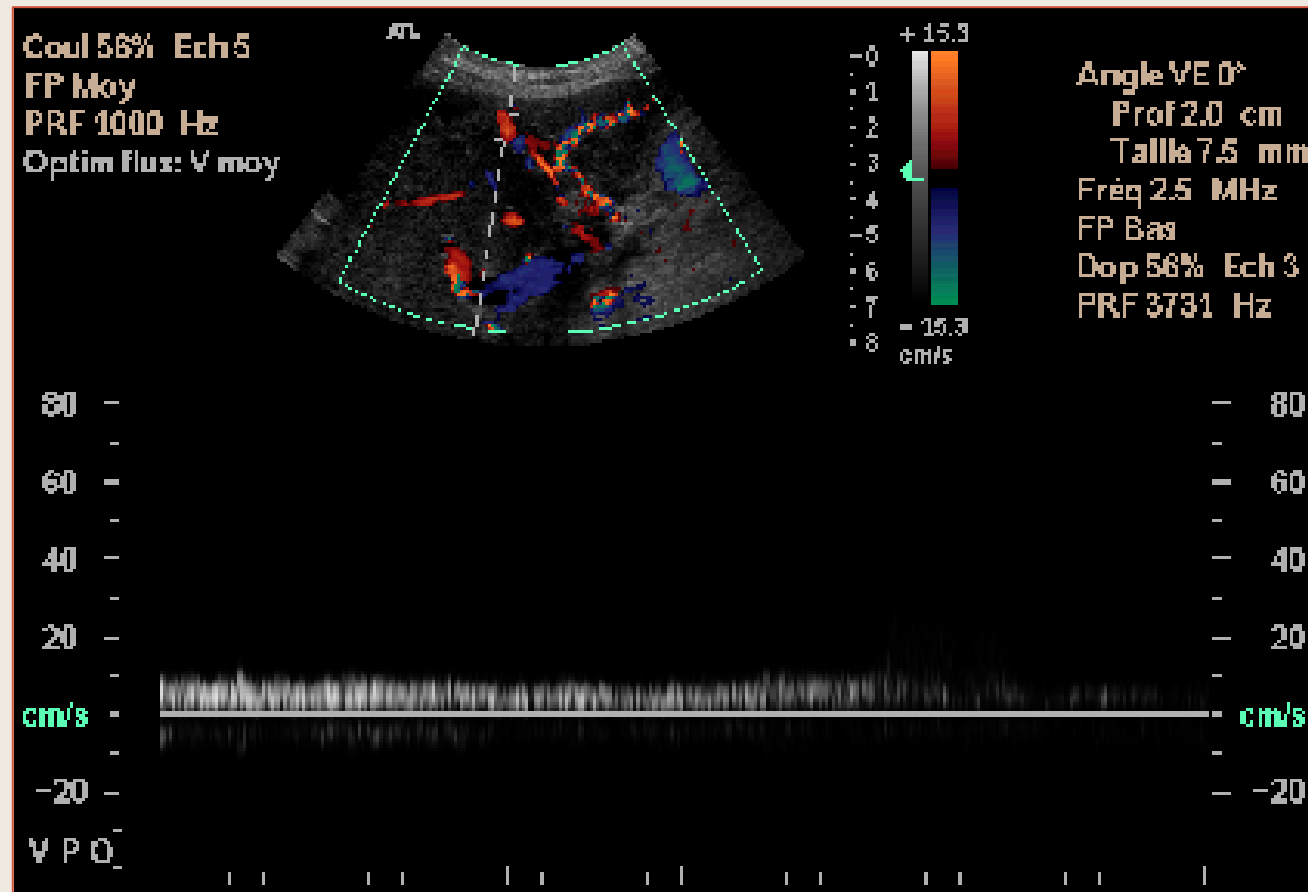
Veine Para-Ombilicale hépatofuge

Dérivations Porto-Caves



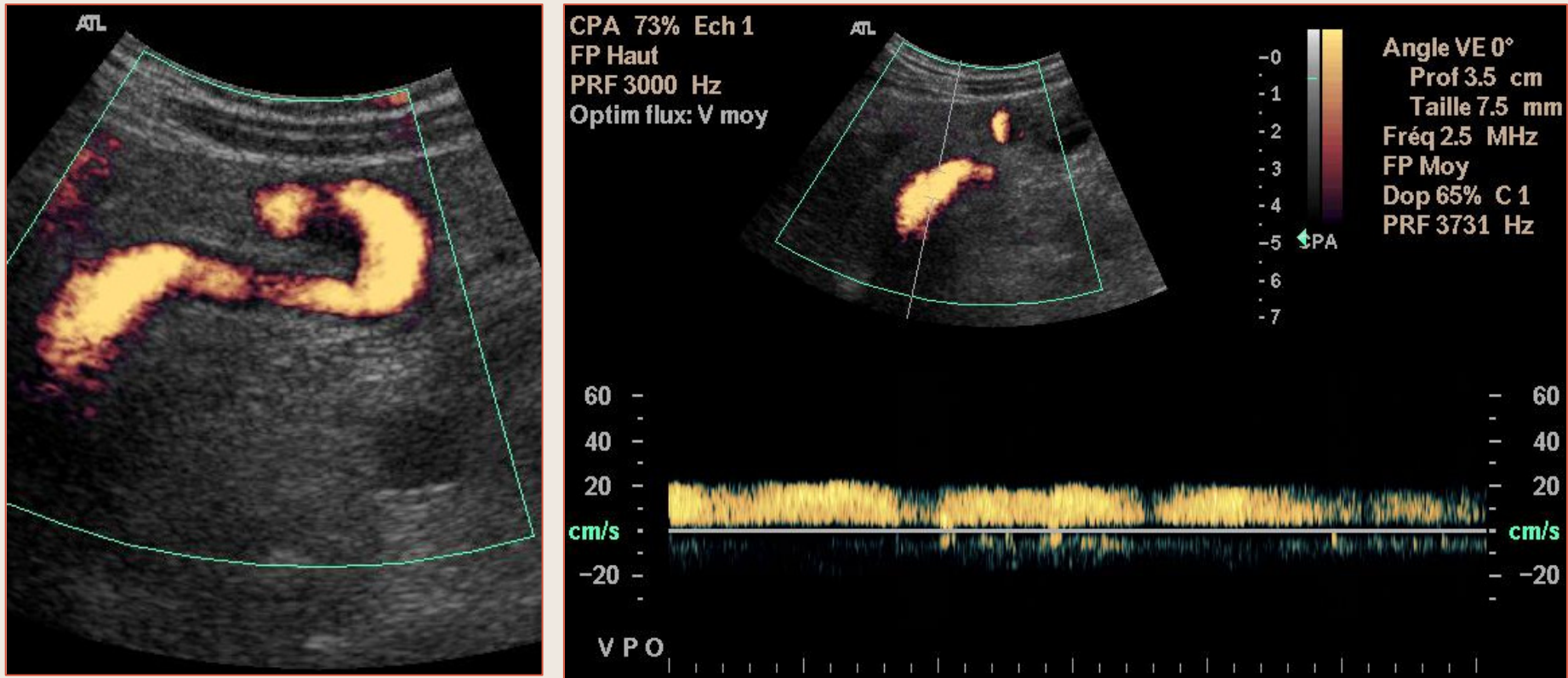
Veine Para-Ombilicale hépatofuge

Hypertension Portale



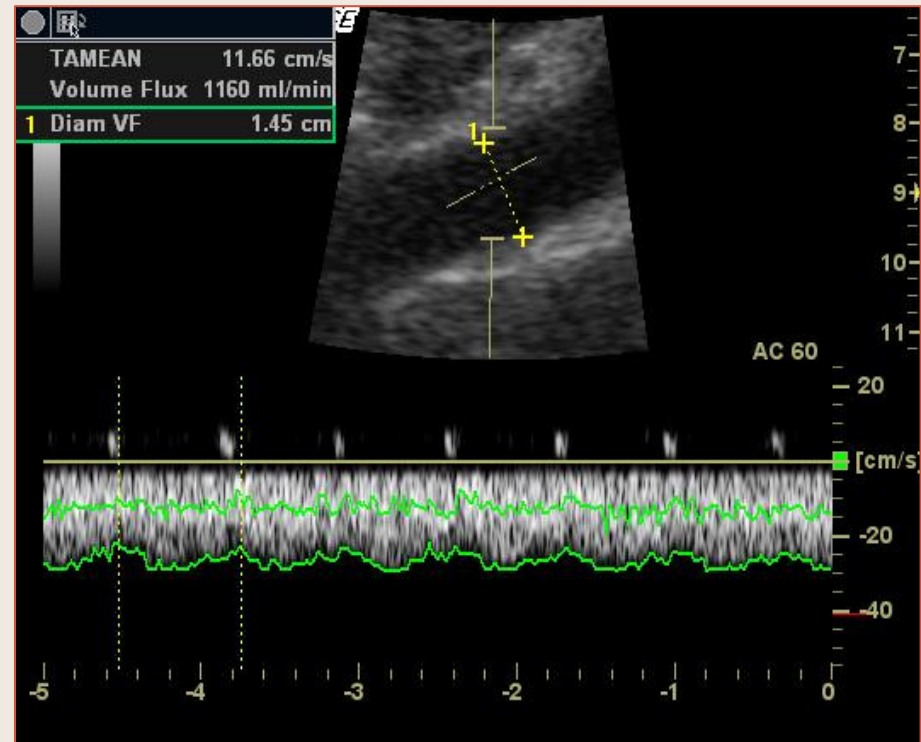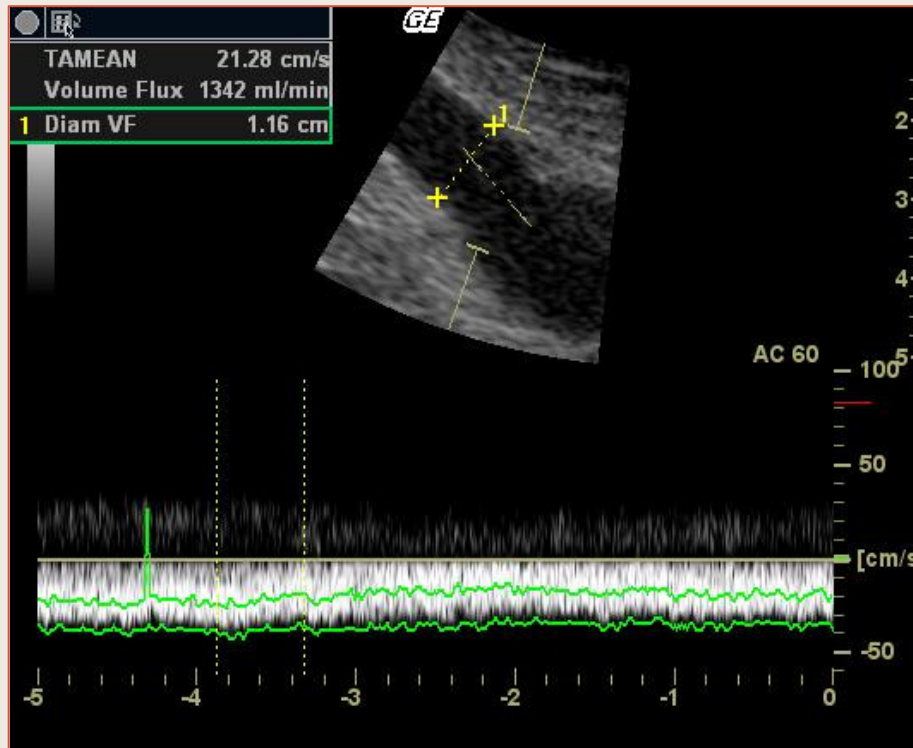
Veine Para-Ombilicale Hépatofuge

Hypertension Portale



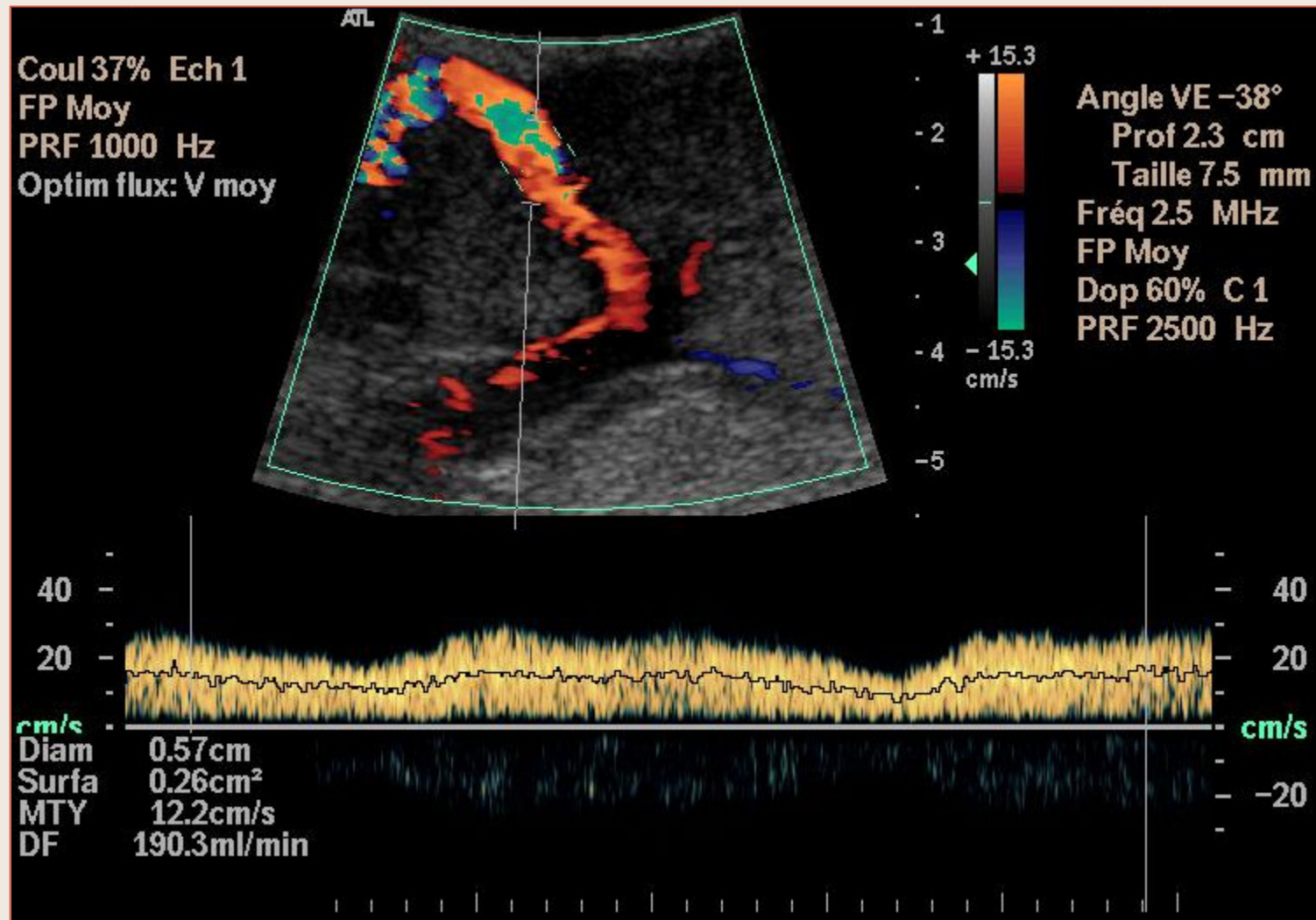
Veine Para-Ombilicale Hépatofuge

Hypertension Portale



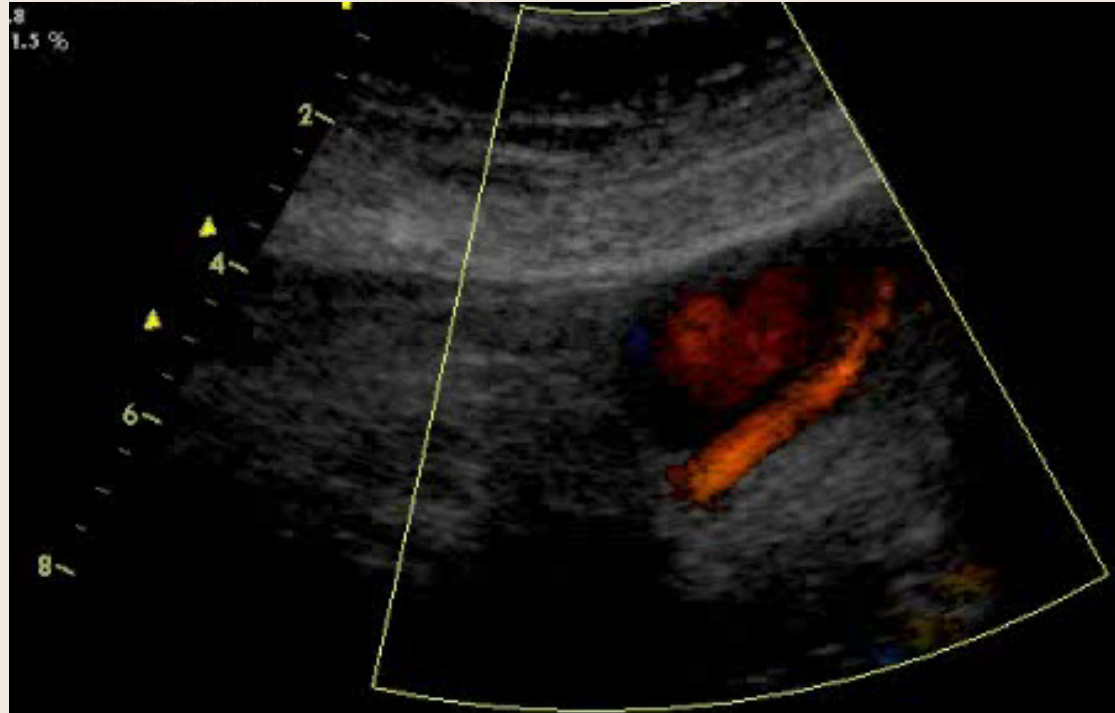
Veine Para-Ombilicale Hépatofuge

Dérivations Porto-Caves



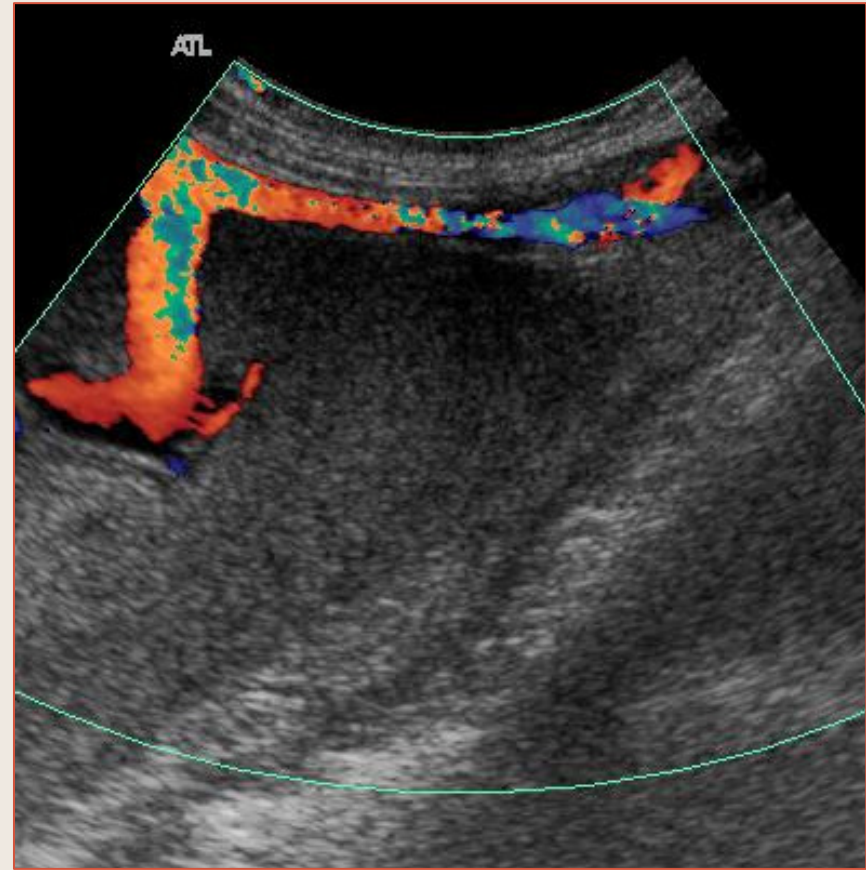
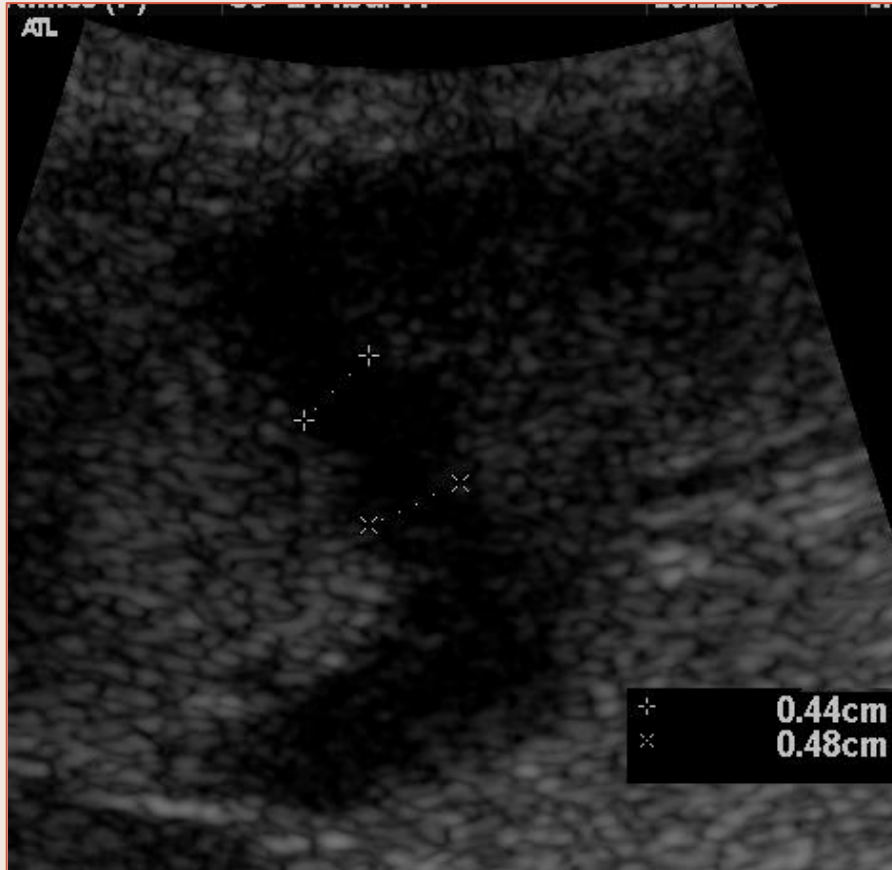Veine Para-Ombilicale Hépatofuge

Dérivations Porto-Caves



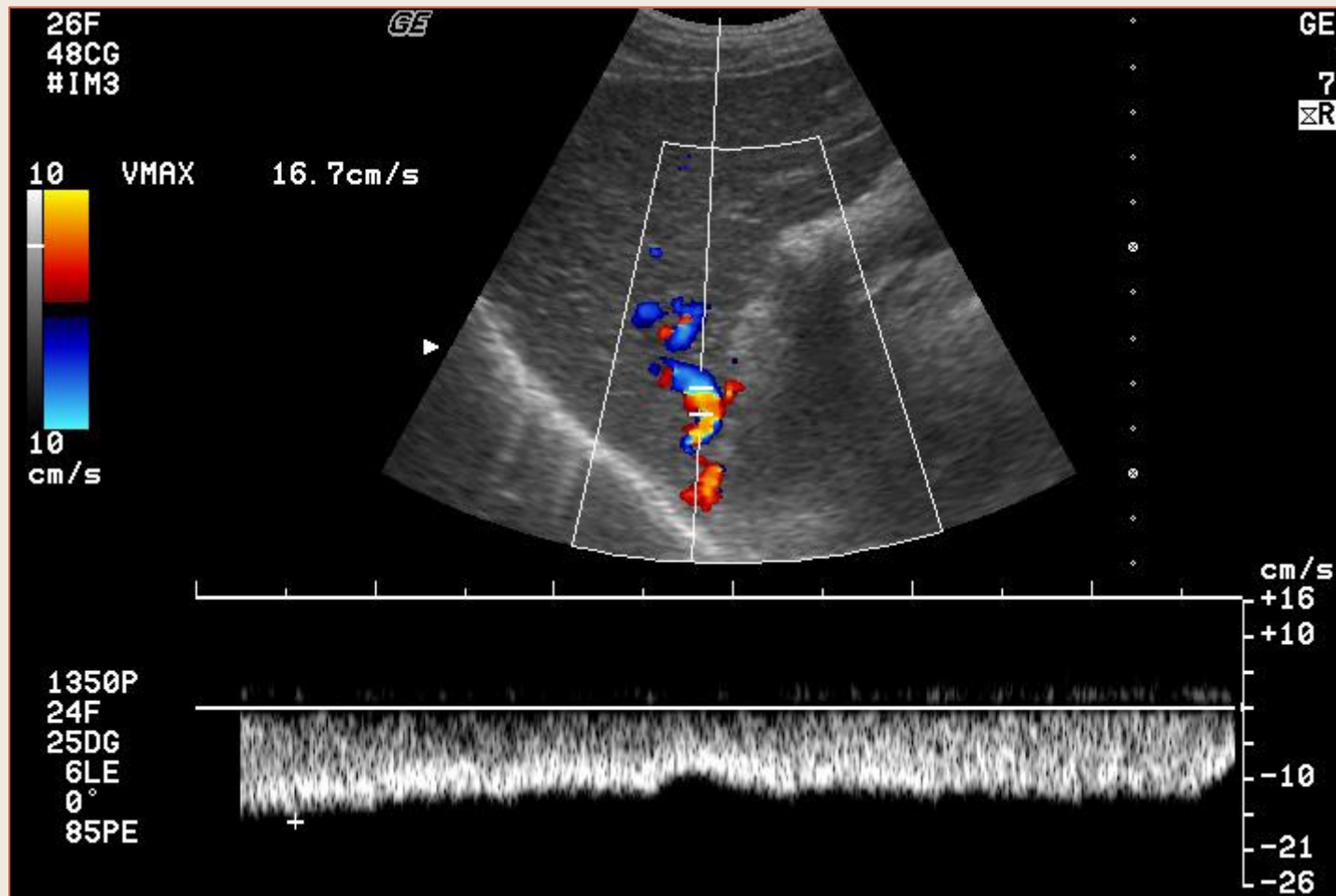
Veine Para-Ombilicale Hépatofuge

Dérivations Porto-Caves



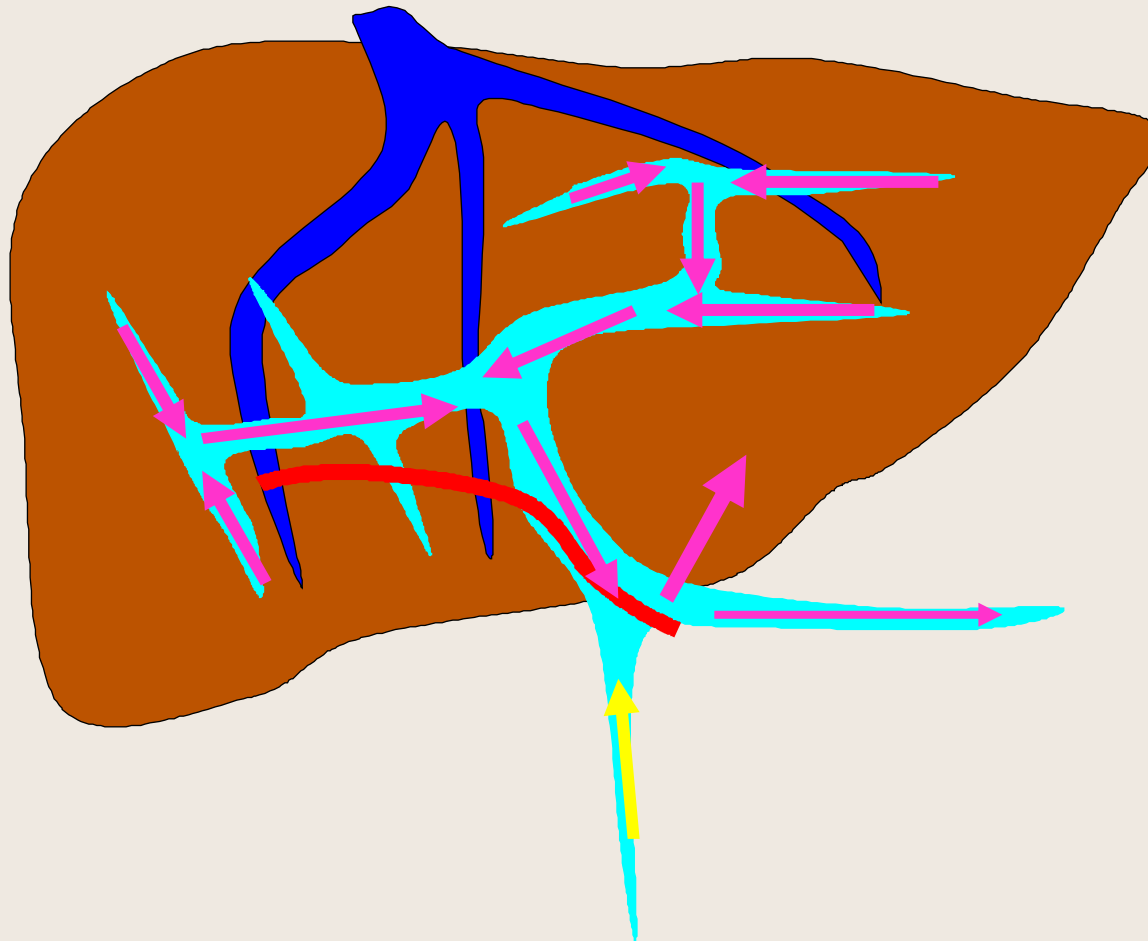Veine Para-Ombilicale Hépatofuge

Dérivations Porto-Caves



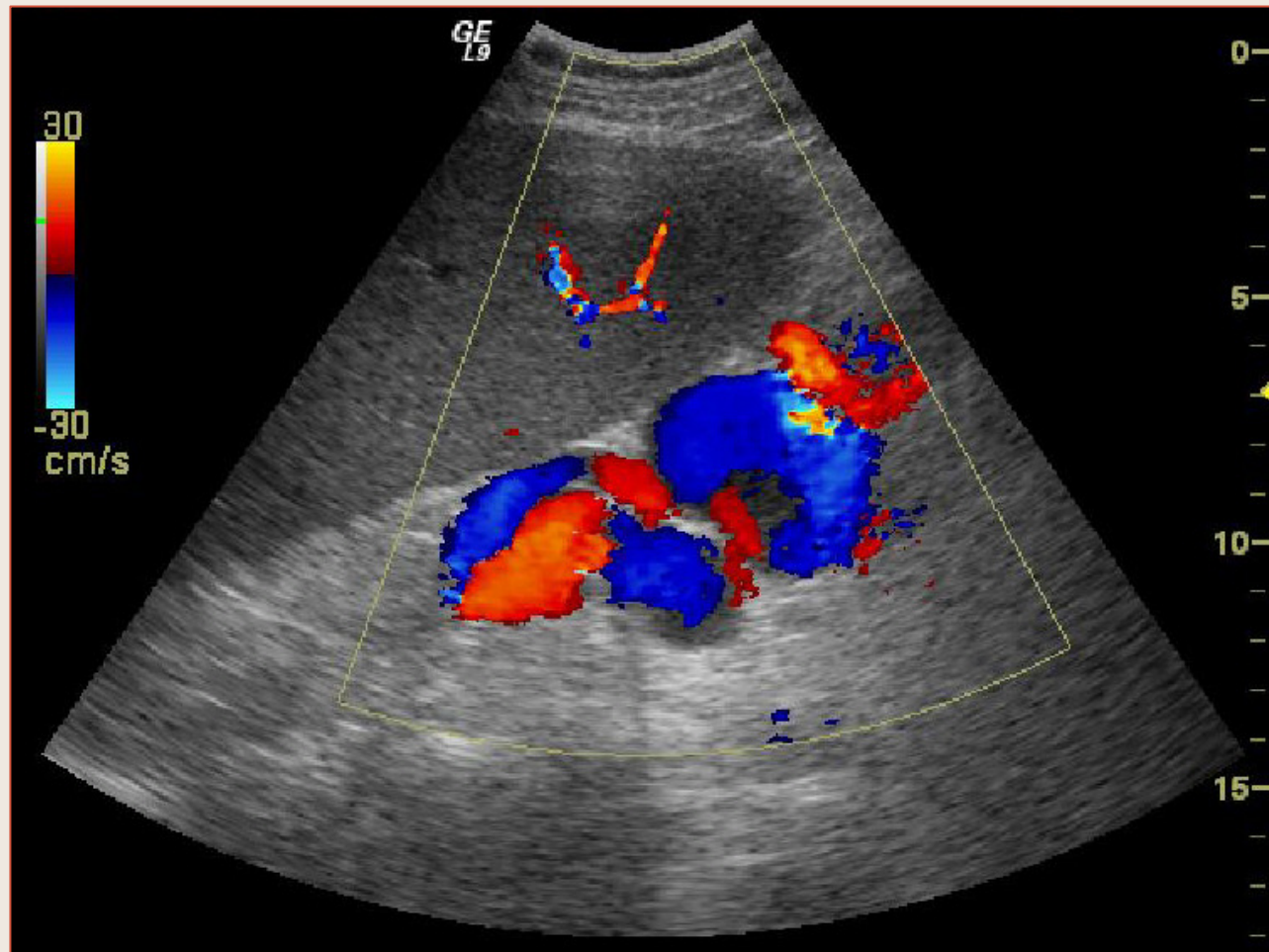
Collatérale porto-systémique spontanée dans le foie droit

Hypertension Portale



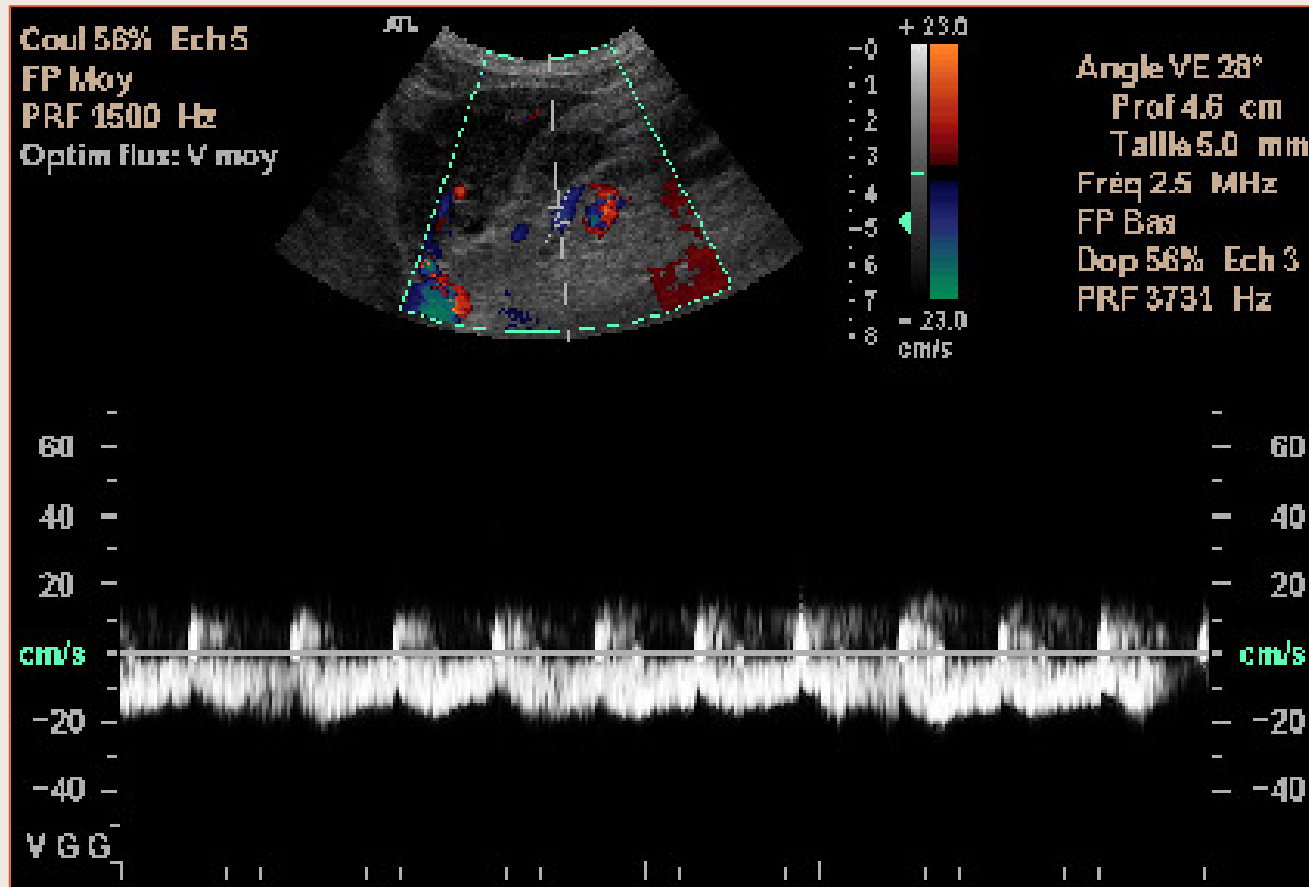
Inversion circulatoire portale intra-hépatique et extra-hépatiques avec **Veine Gastrique Gauche Hépatofuge**

Hypertension Portale



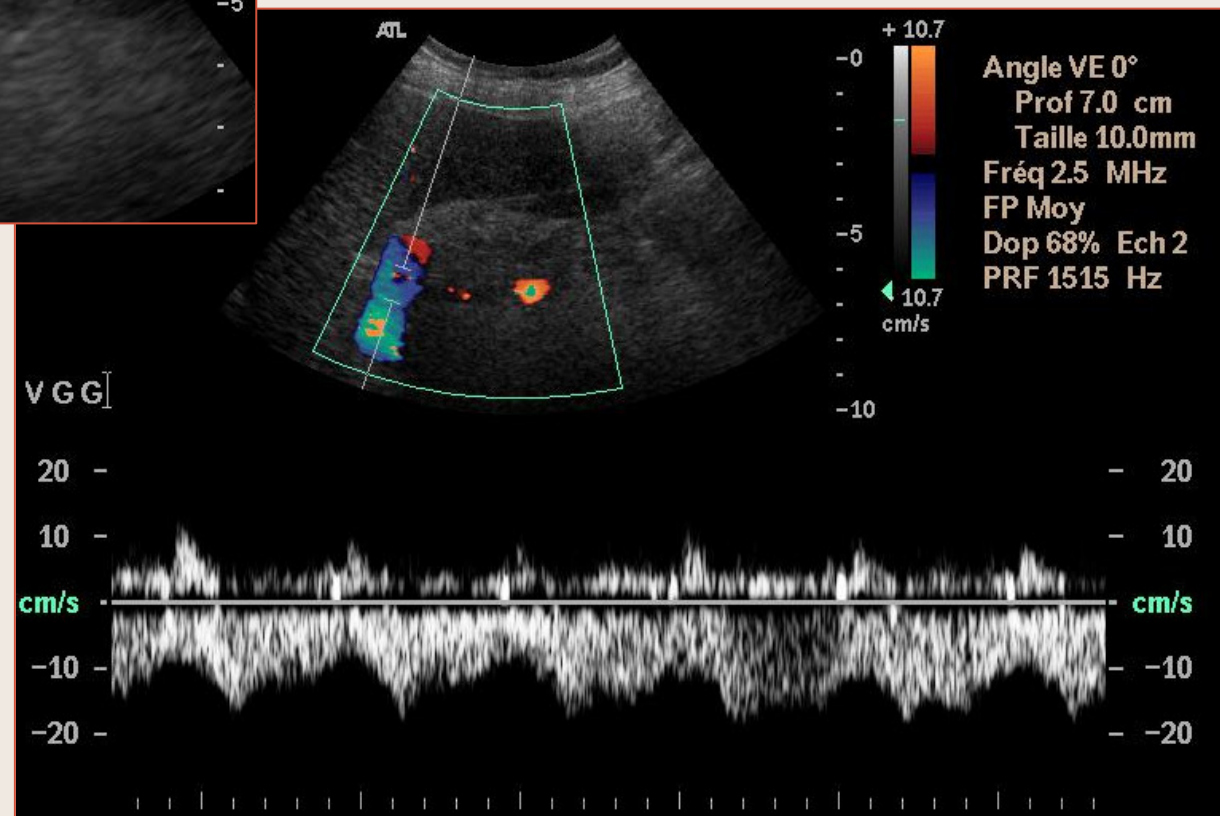
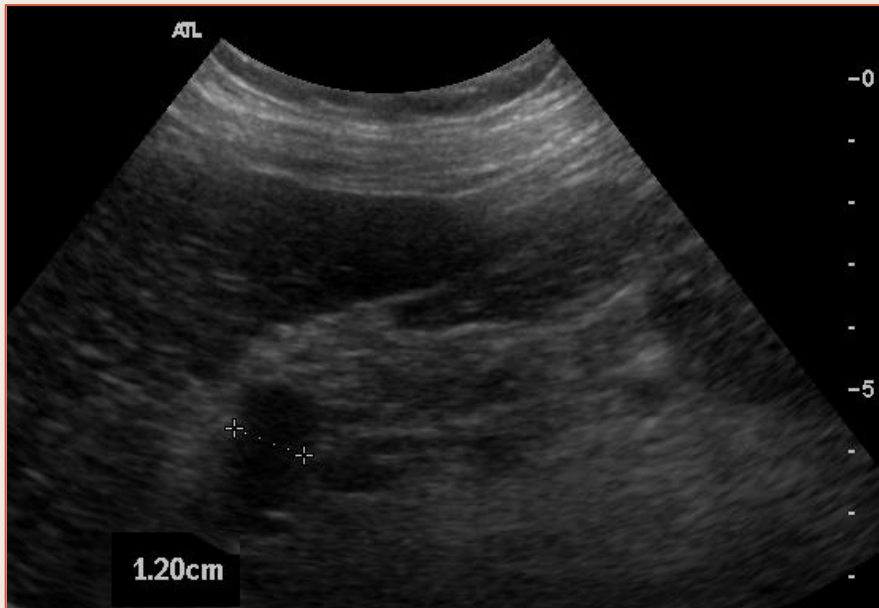Volumineuses Varices à partir de la Veine Gastrique Gauche

Hypertension Portale



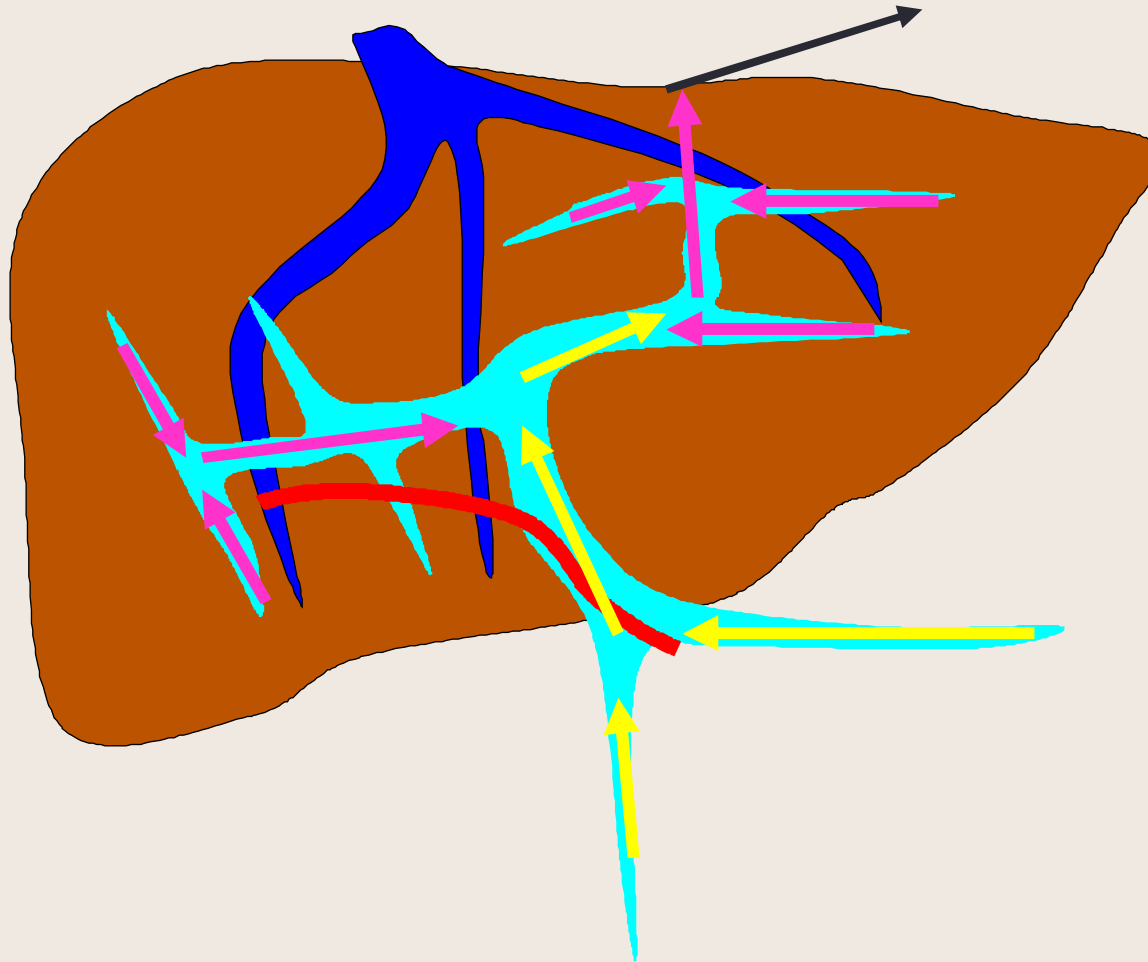
Veine Gastrique Gauche Hépatofuge

Dérivations Porto-Caves



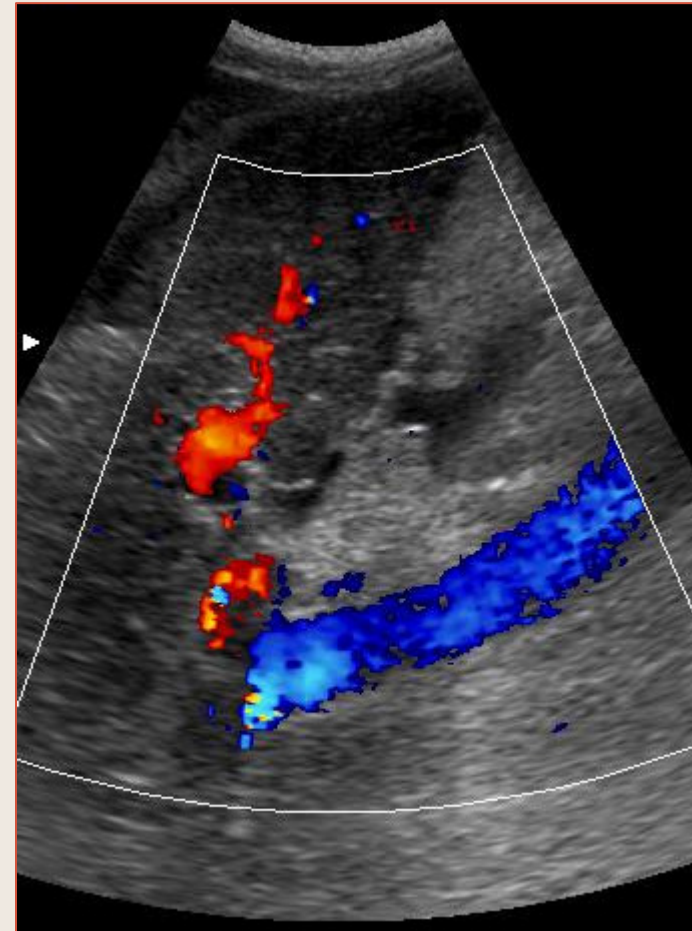
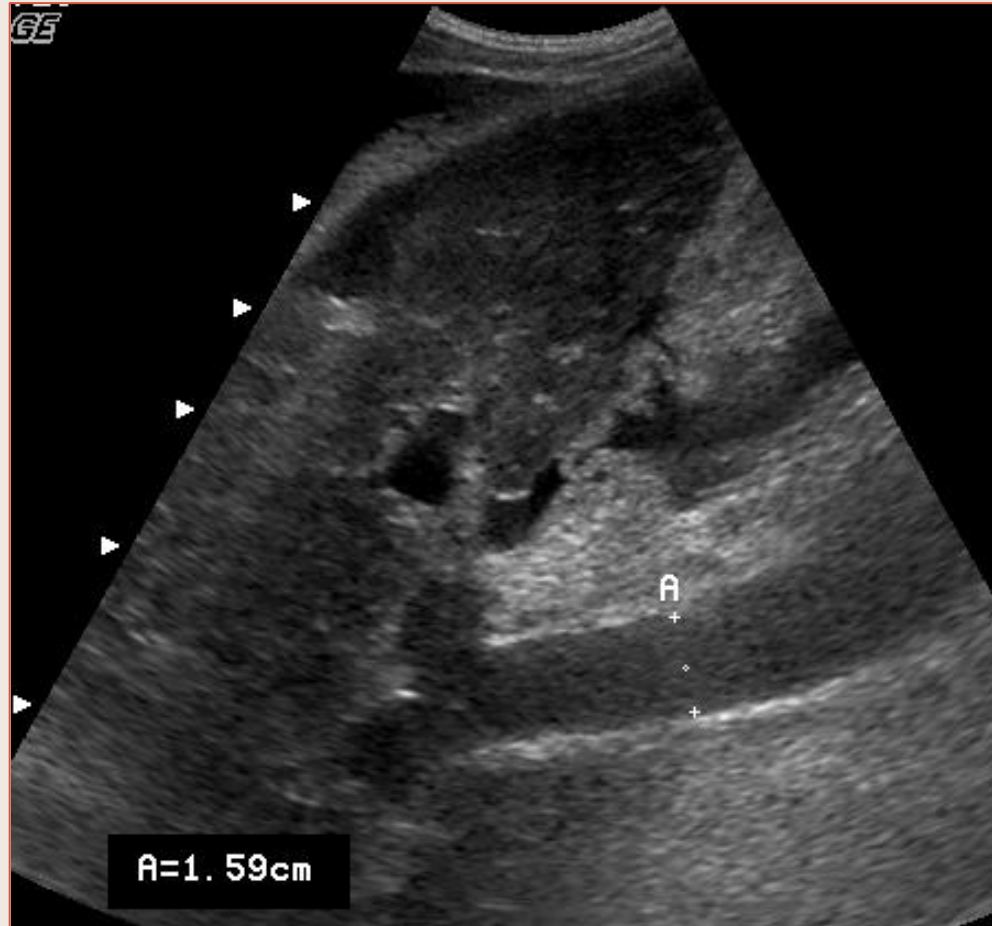
Veine
Gastrique
Gauche
hépatofuge

Hypertension Portale



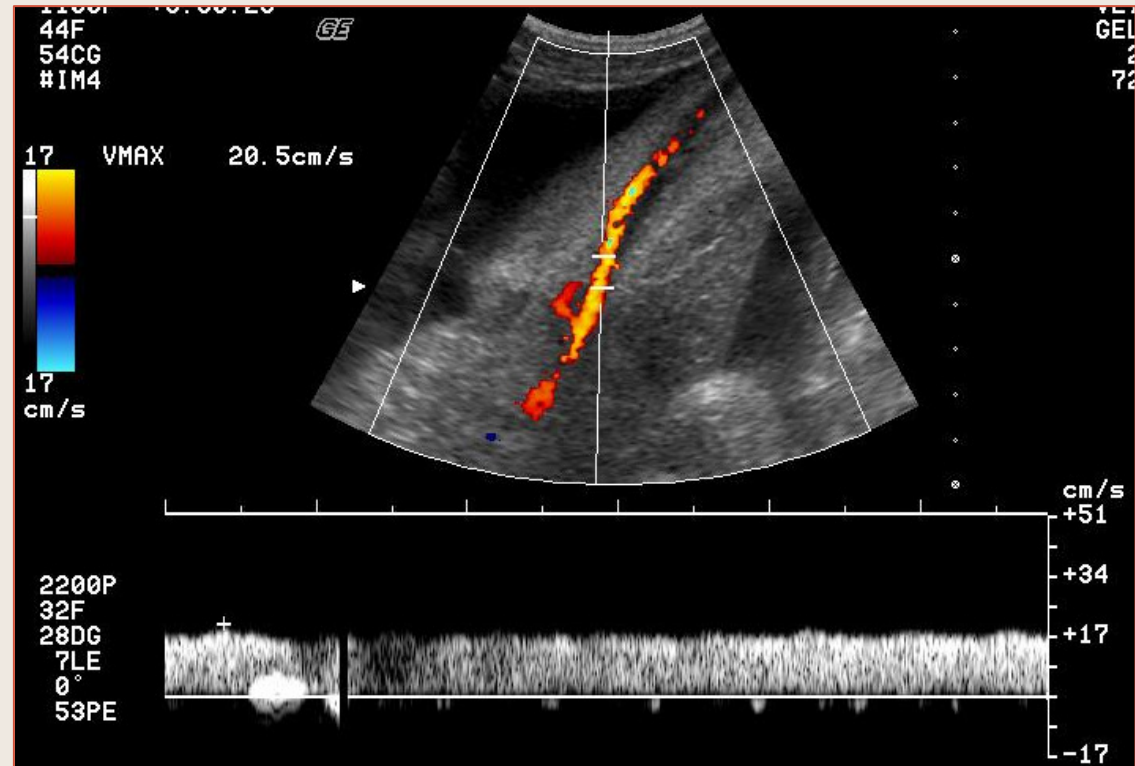
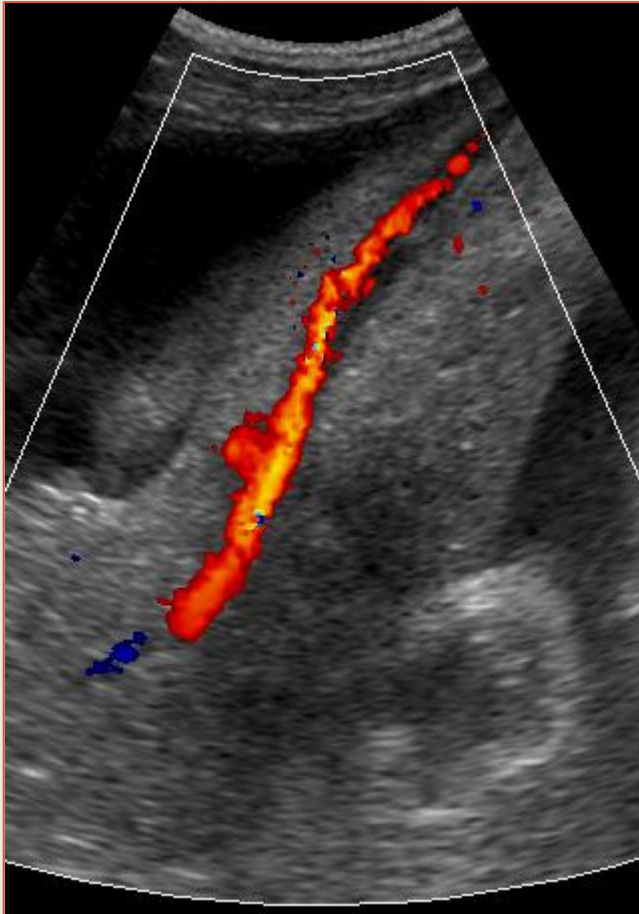
Inversion circulatoire portale intra-hépatique droite
et veine para-ombilicale hépatofuge

Dérivations Porto-Caves



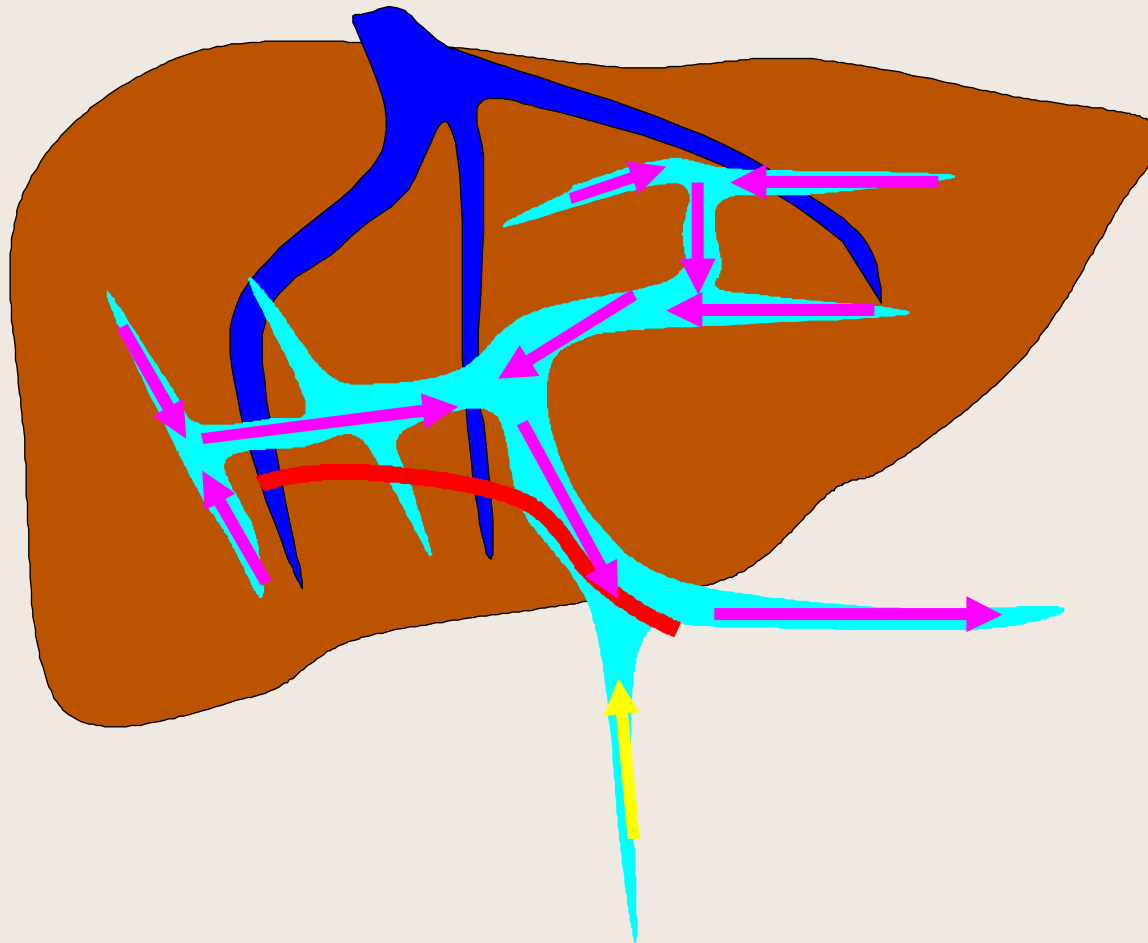Ascite, « Congestion Portale », Veine Paraombilicale hépatofuge

Dérivations Porto-Caves



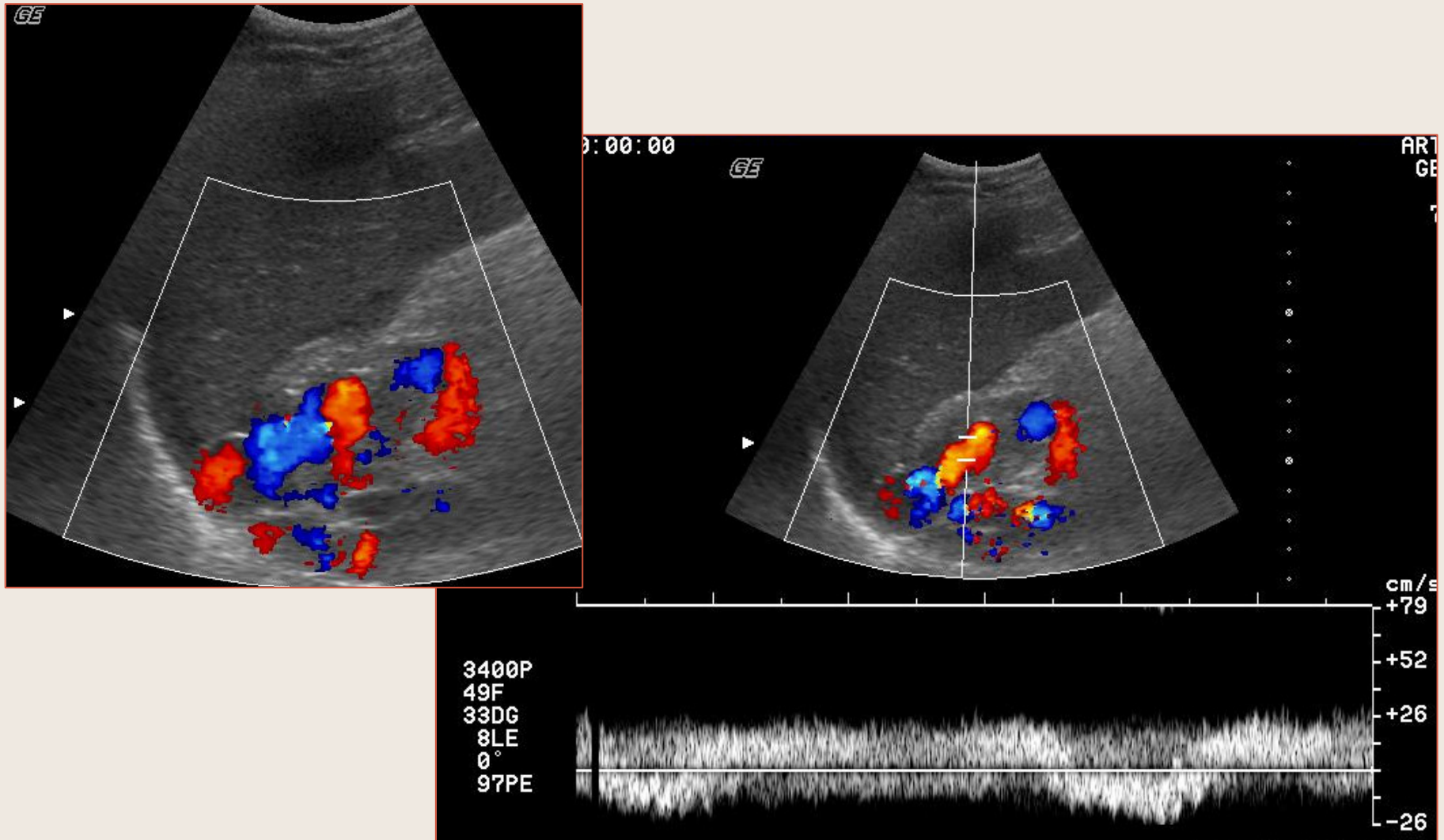
Veine Paraombilicale hépatofuge

Hypertension Portale



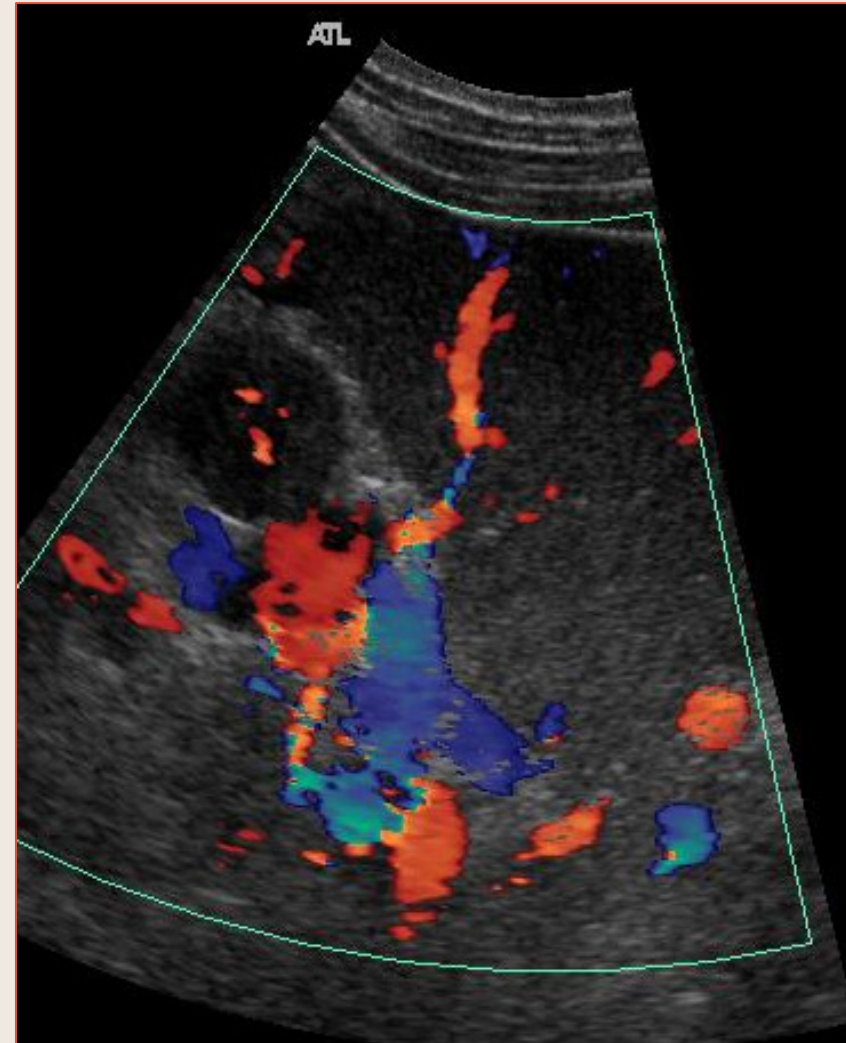
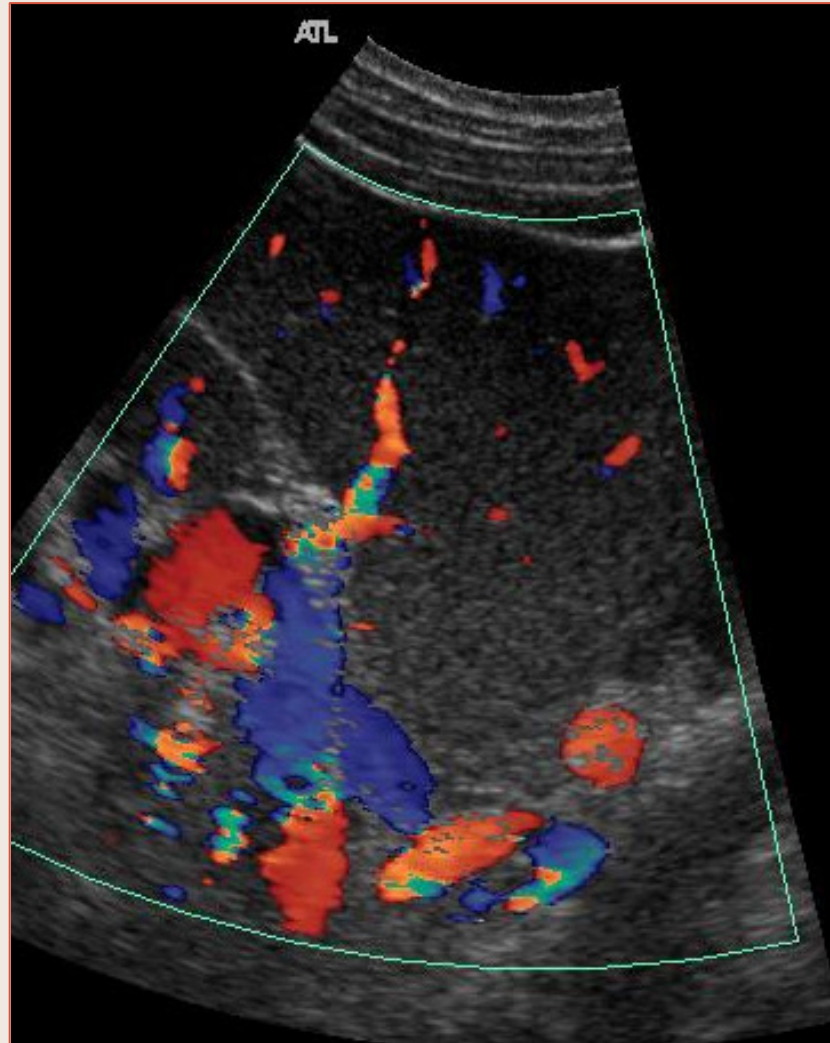
Inversion circulatoire portale intra-hépatique et extra-hépatique avec shunts spléno-rénaux

Dérivations Porto-Caves



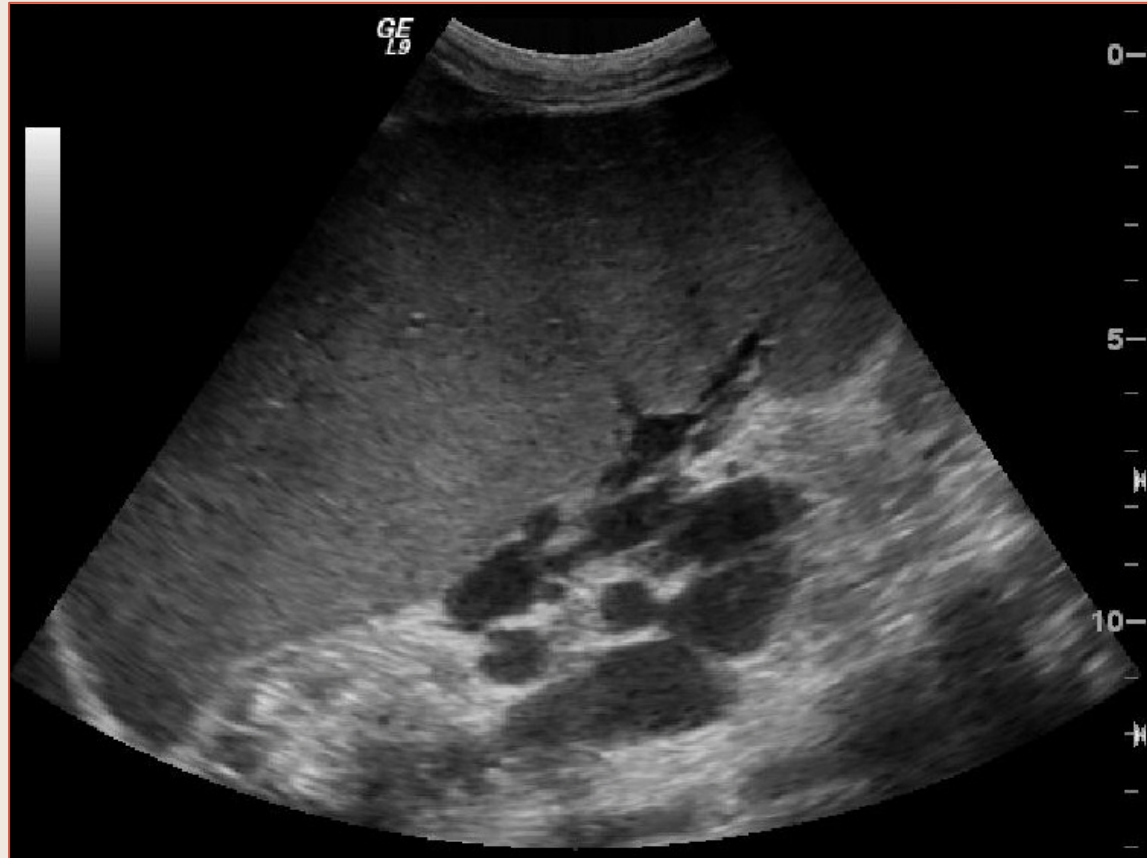
Varices au hile Splénique

Dérivations Porto-Caves



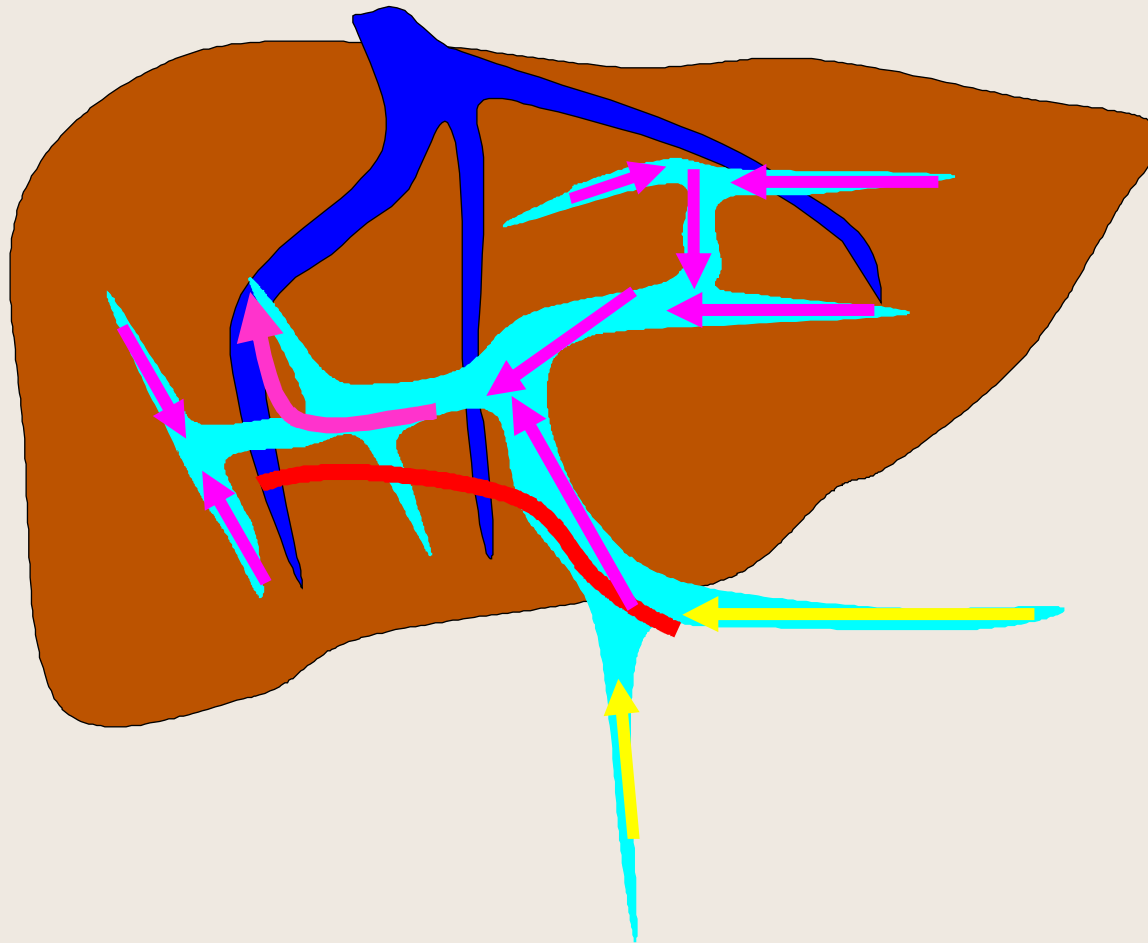
Varices au hile Splénique

Dérivations Porto-Caves



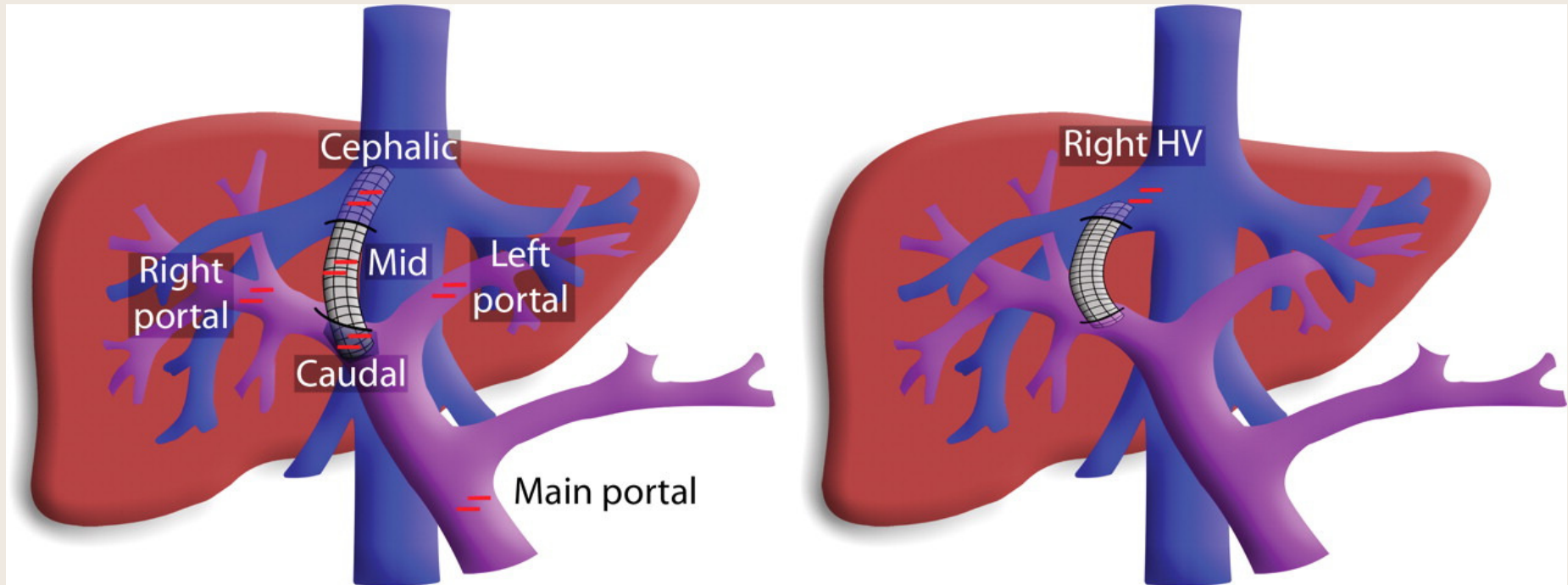
Varices au hile Splénique

Hypertension Portale



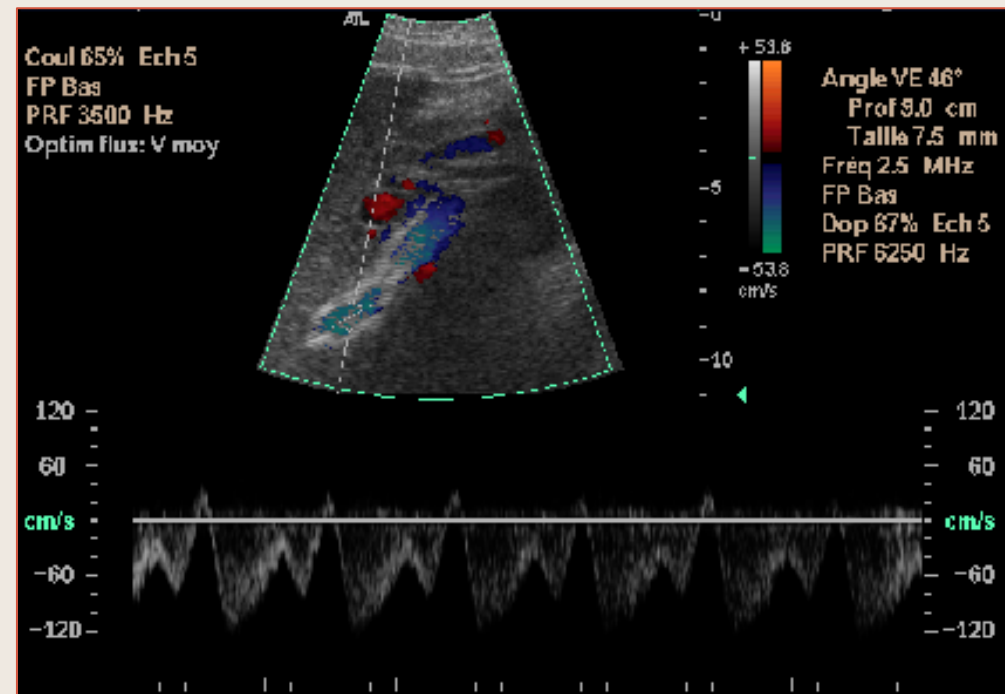
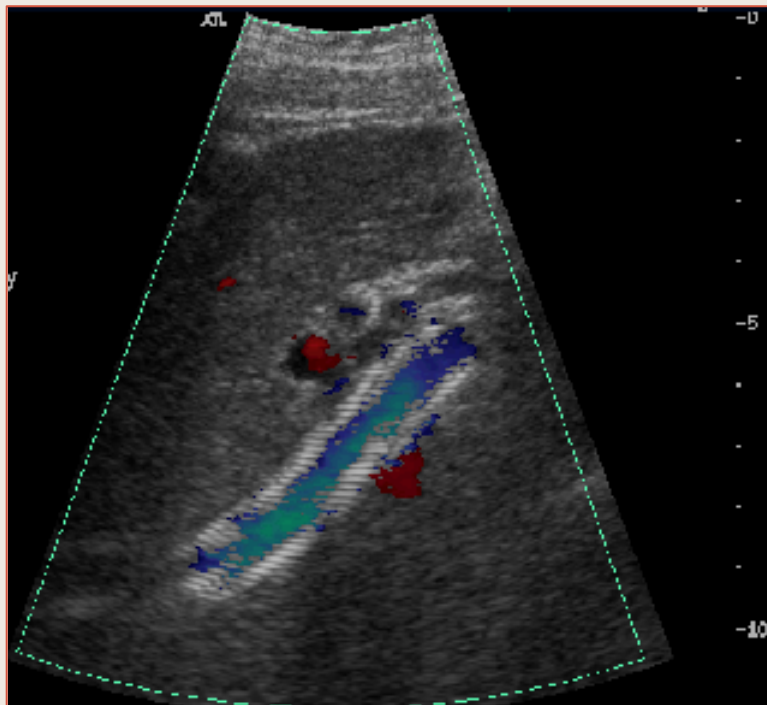
Shunt Porto-Systémique Intra-Hépatique (TIPSS)

Hypertension Portale



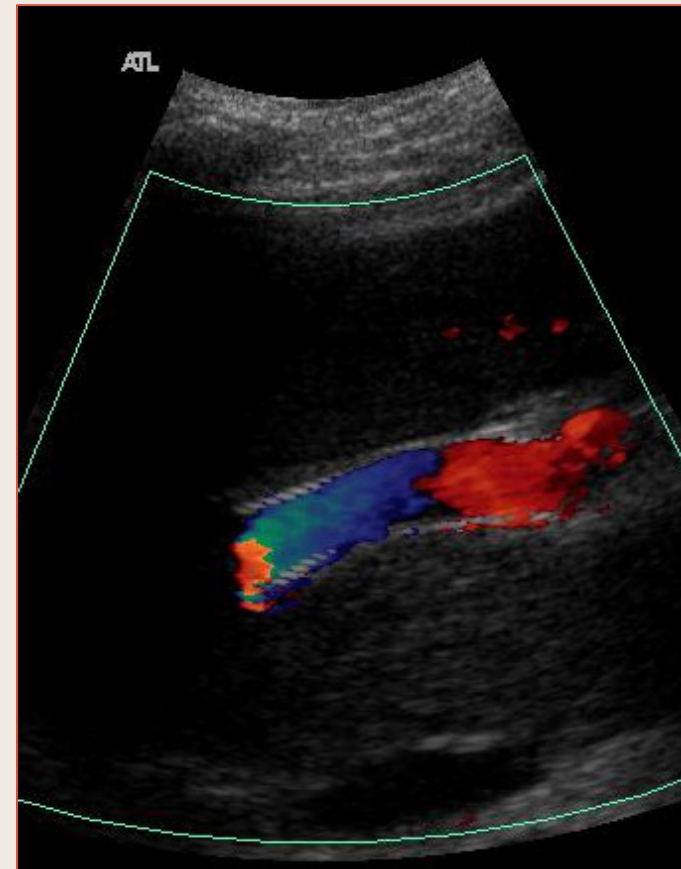
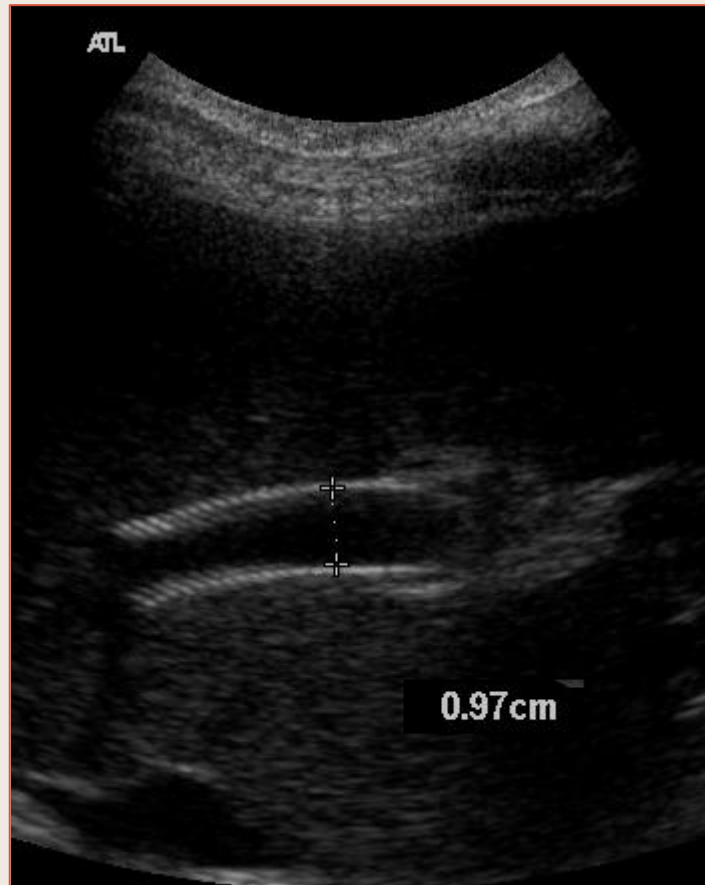Shunt Porto-Systémique Intra-Hépatique (TIPSS)

Shunt Porto-Systemique Intra-Hépatique



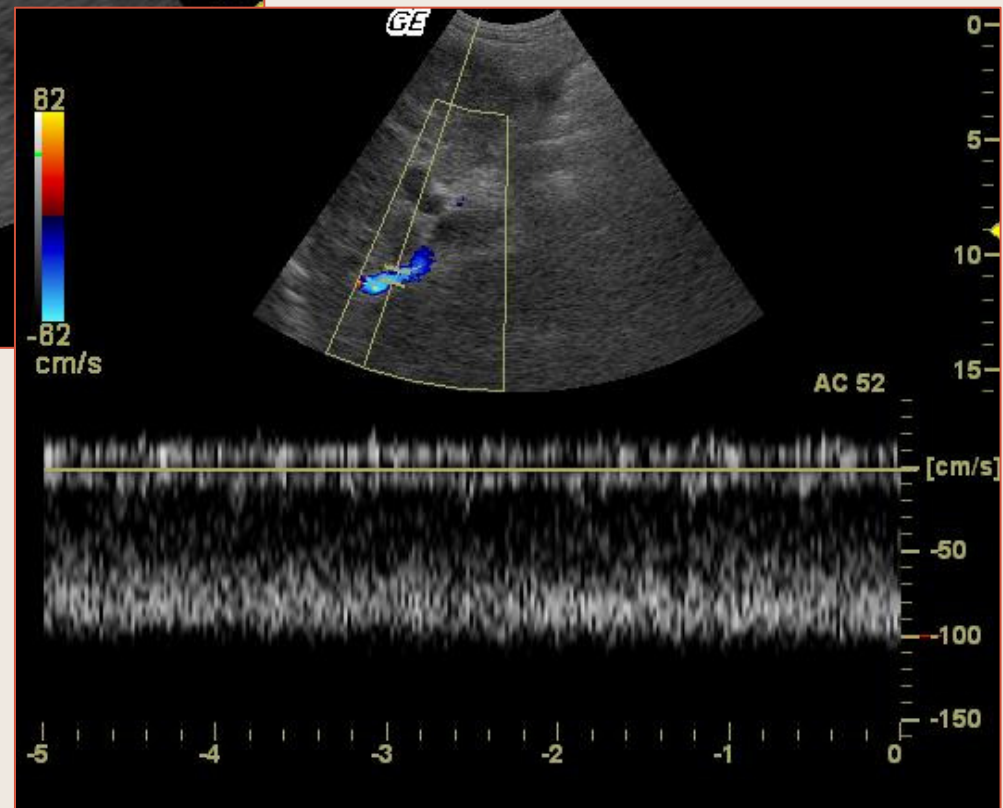
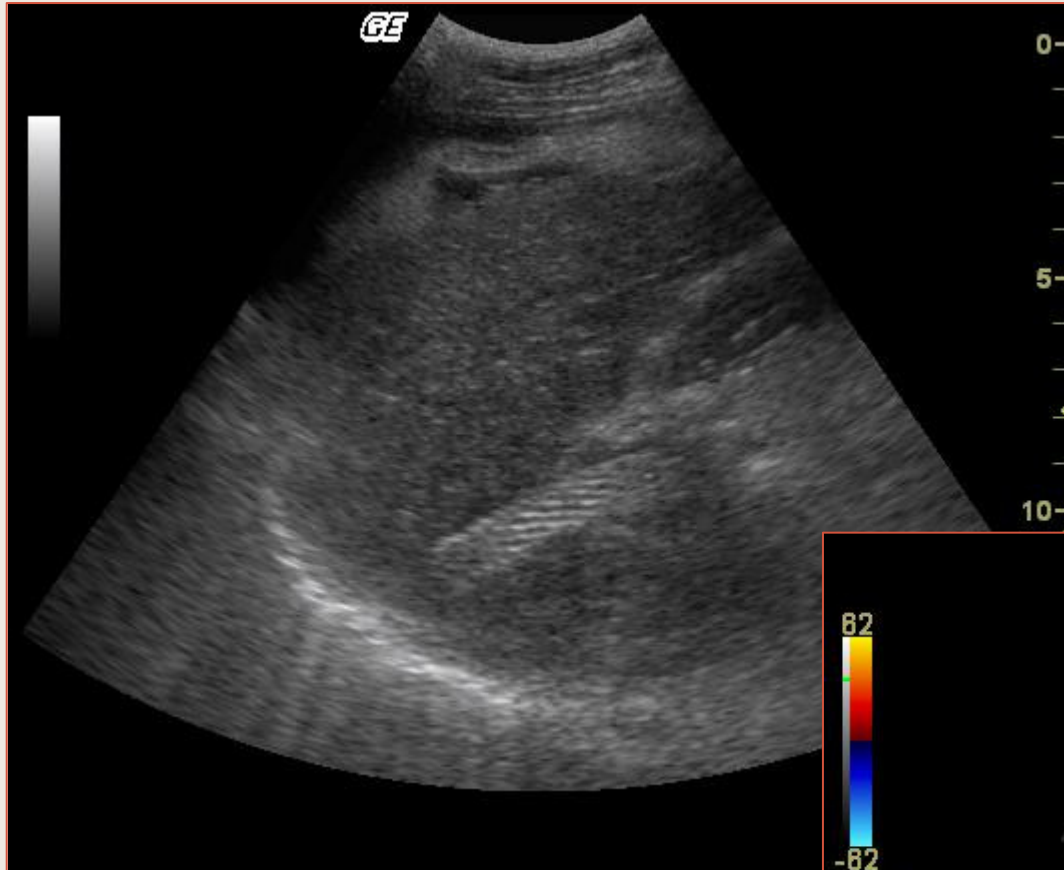
Flux de modulation cave marquée dans un T.I.P.S.

Shunt Porto-Systemique Intra-Hépatique



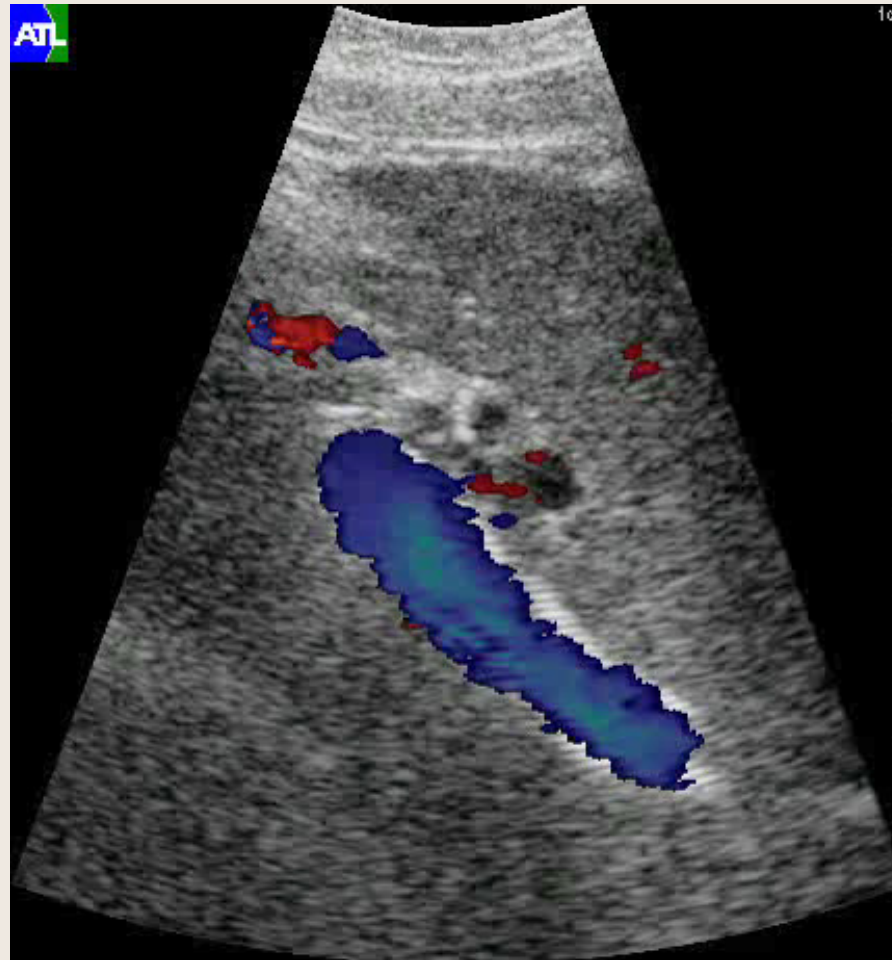
T.I.P.S. perméable

Shunt Porto- Systémique Intra-Hépatique



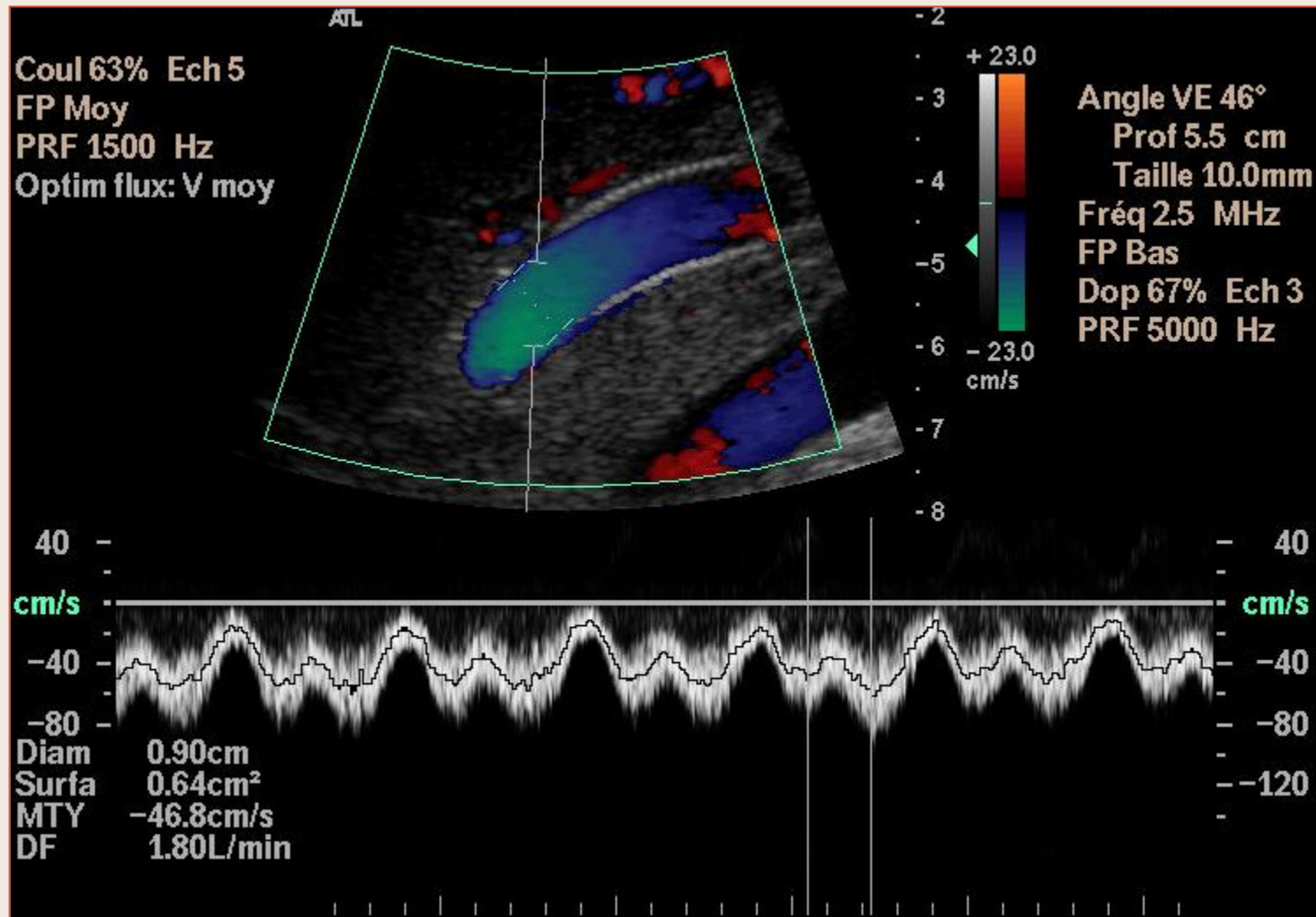
T.I.P.S. perméable
TAMxV = 100 cm/s

Shunt Porto-Systemique Intra-Hépatique



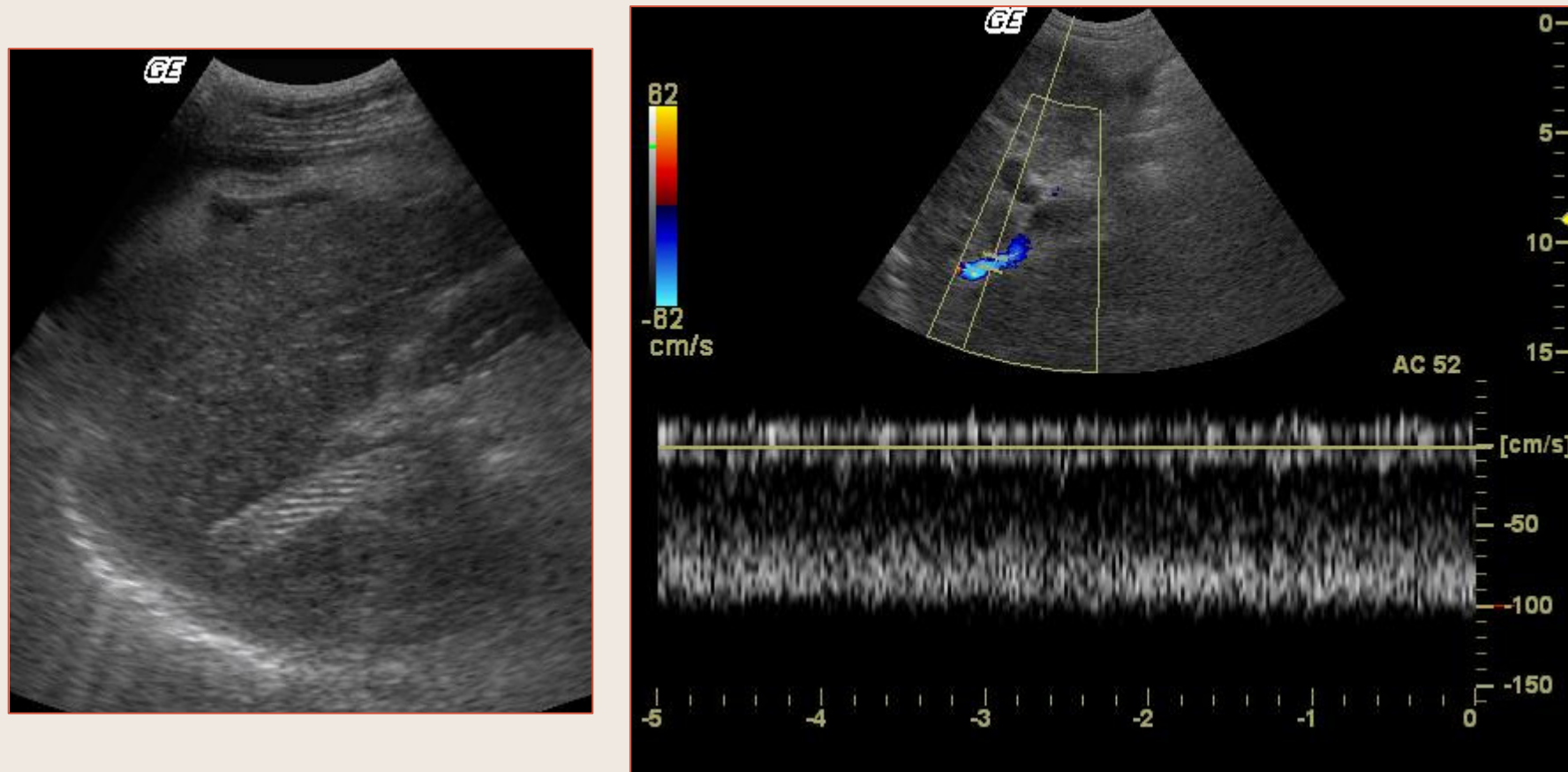
Shunt Porto-Systemique Intra-Hépatique (TIPSS)

Shunt Porto-Systemique Intra-Hépatique



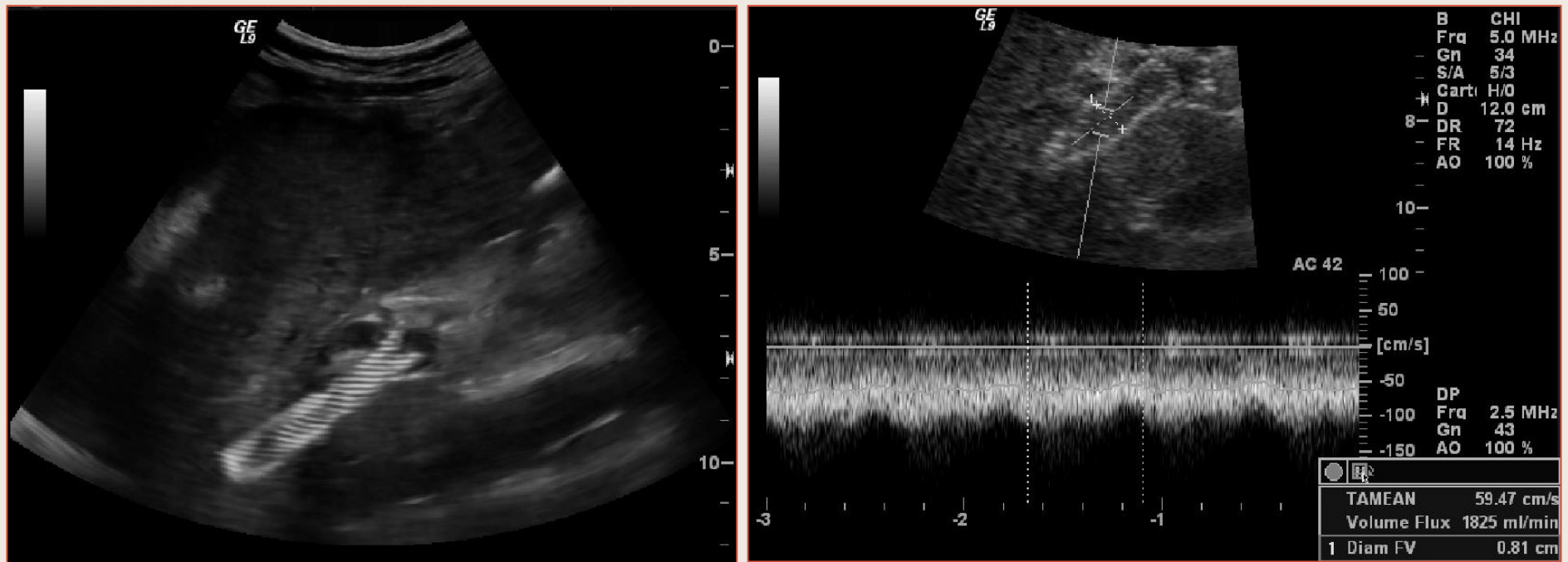
Shunt Porto-Systemique Intra-Hépatique (TIPSS) perméable.
Débit 1330 ml/min, fortement modulé

Shunt Porto-Systemique Intra-Hépatique



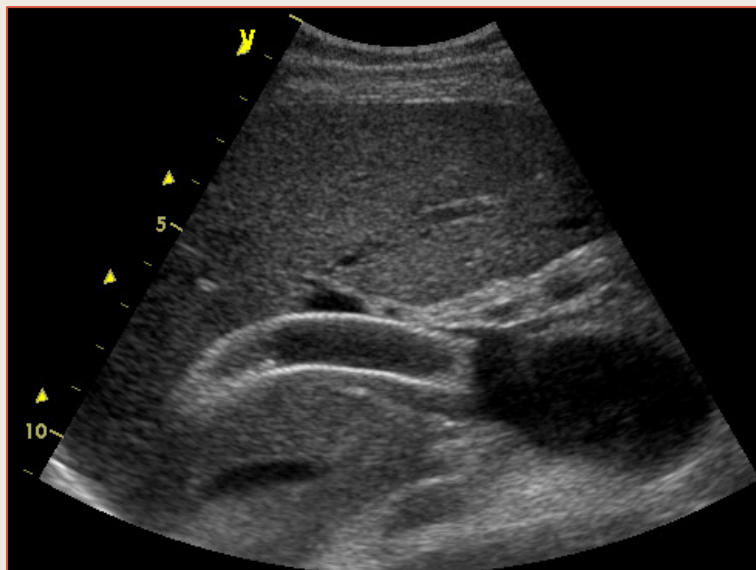
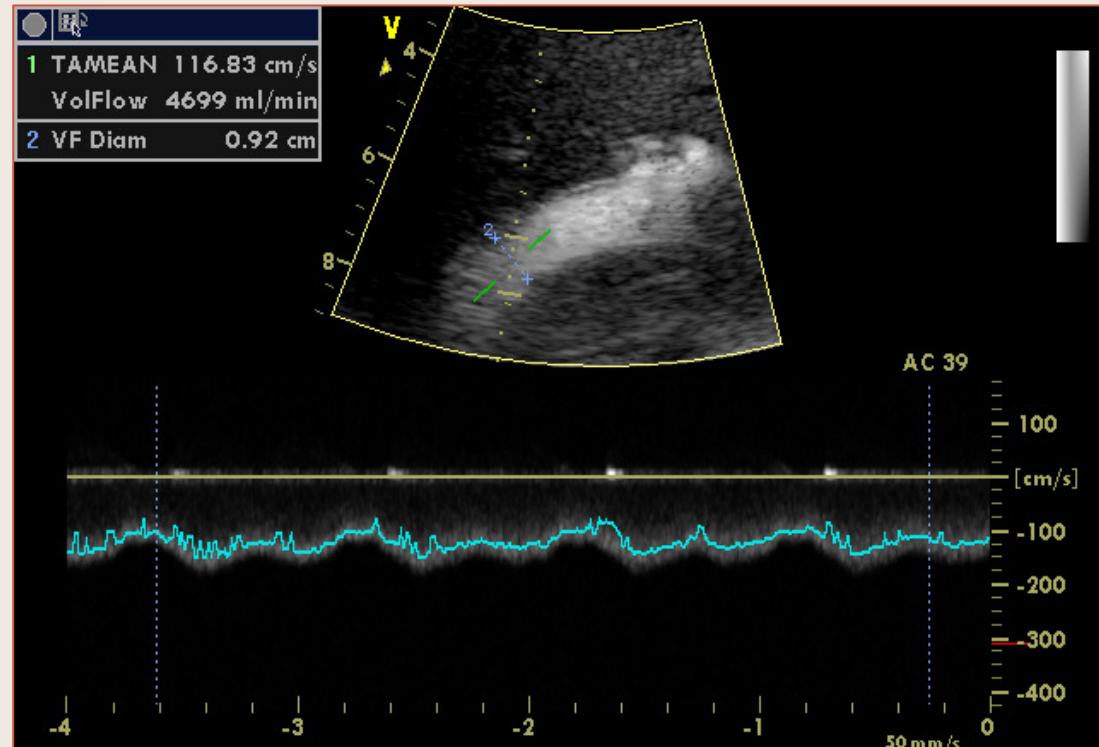
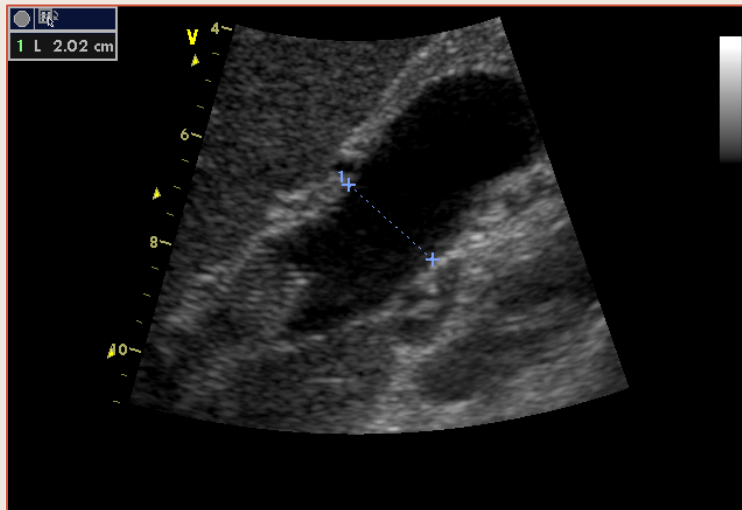
Shunt Porto-Systemique Intra-Hépatique (TIPSS) perméable.
Flux non modulé – Vitesse maximale 100 cm/s

Shunt Porto-Systemique Intra-Hépatique



Shunt Porto-Systemique Intra-Hépatique (TIPSS) perméable –
Hyperdynamie Splanchnique

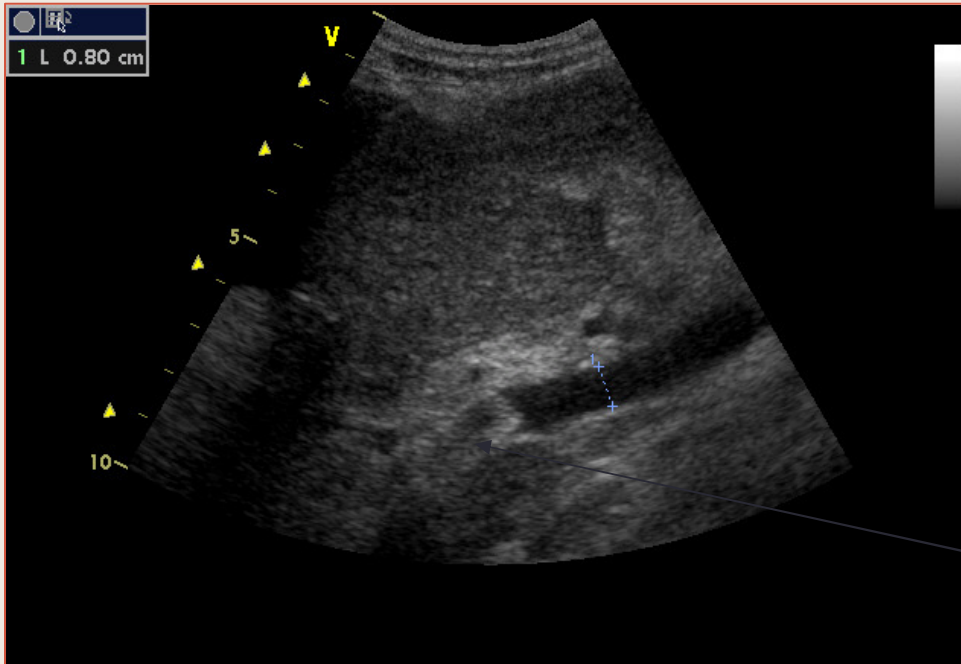
Shunt Porto-Systémique Intra-Hépatique



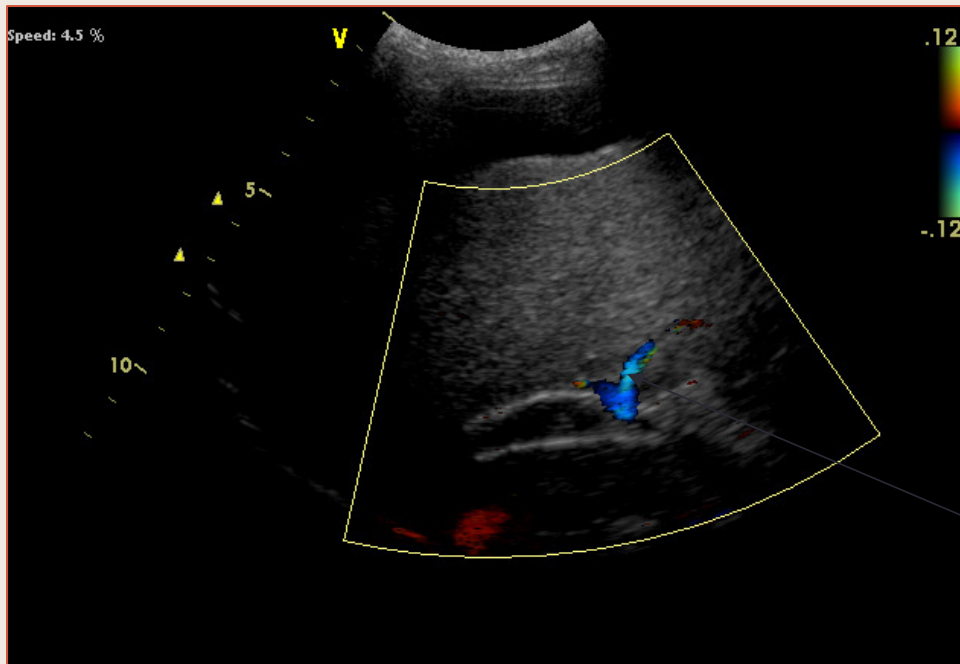
Shunt Porto-Systémique Intra-Hépatique
(TIPSS) perméable
Hyperdébit splanchnique

Tronc veineux portal dilaté

Thrombose de Shunt Porto-Systemique Intra-Hépatique (TIPS)



TIPS



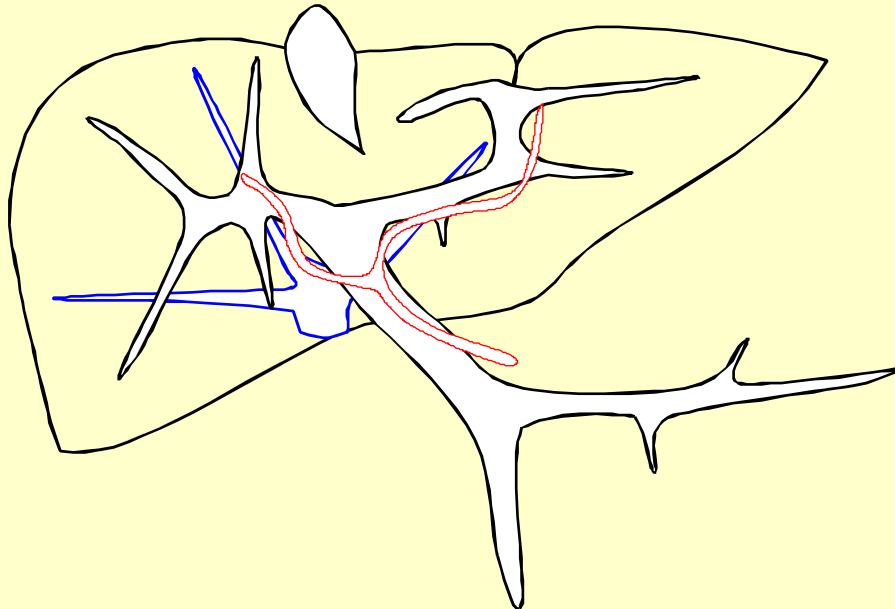
Flux portal inversé

Bilan de la Circulation Hépatique

Centre Hospitalier Universitaire de Nîmes - Département d'Imagerie Médicale
Unité d'Exploration Vasculaire

C.H.U. BP 26 - 30029 - Nîmes - Tél. Hôpital G. Doumergue 04 66 68 33 13 - Hôpital Caremeau 04 66 68 34 45

EXAMEN ULTRASONOGRAPHIQUE de la CIRCULATION HEPATIQUE



NOM:

Prénom:

D.N. :

Date : / / 19..

A. Hépatique		Vitesse moyenne (cm.s)	V. Porte	Shunt
	I.R.			
Commune:				
à Droite:				
à Gauche:				
V. Hépatiques		Diamètre (mm)		
	Flux			
Droite				
Moyenne				
Gauche				
		Débit (ml/min)		

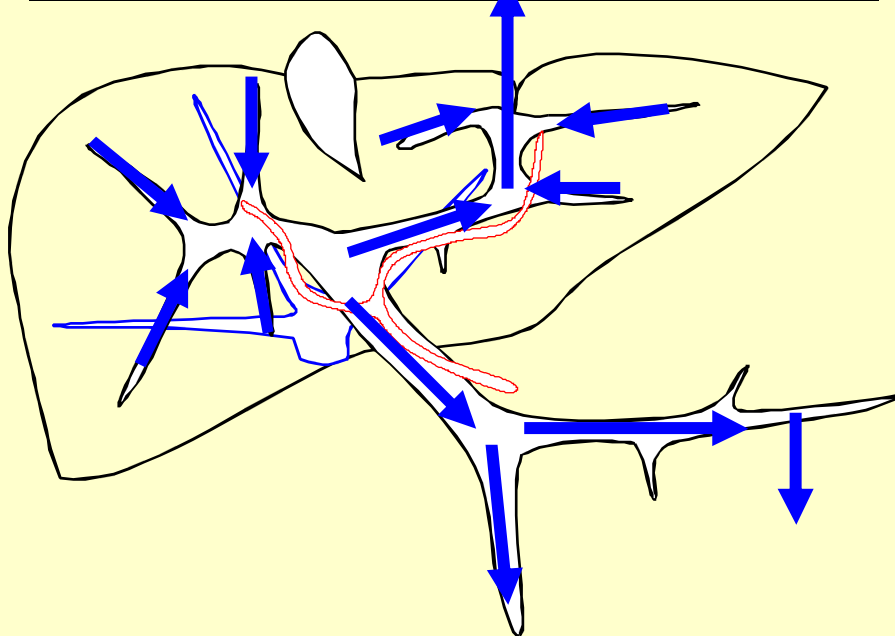
CONCLUSIONS:

Bilan de la Circulation Hépatique

Centre Hospitalier Universitaire de Nîmes - Département d'Imagerie Médicale
Unité d'Exploration Vasculaire

C.H.U. BP 26 - 30029 - Nîmes - Tél. Hôpital G. Doumergue 04 66 68 33 13 - Hôpital Caremeau 04 66 68 34 45

EXAMEN ULTRASONOGRAPHIQUE de la CIRCULATION HEPATIQUE



NOM:

Prénom:

D.N. :

Date : / / 19..

A. Hépatique		Vitesse moyenne (cm.s)	V. Porte	Shunt
	I.R.			
Commune:				
à Droite:				
à Gauche:				
V. Hépatiques		Diamètre (mm)		
	Flux			
Droite				
Moyenne				
Gauche				
		Débit (ml/min)		

CONCLUSIONS:

Système porte extra et intra-hépatique perméable. Inversion circulatoire portale intra-hépatique globale avec large veine para-ombilicale hépatofuge. Inversion circulatoire dans le tronc de la veine porte et la veine splénique, en direction de shunts spléno-rénaux spontanés.